Nephrology

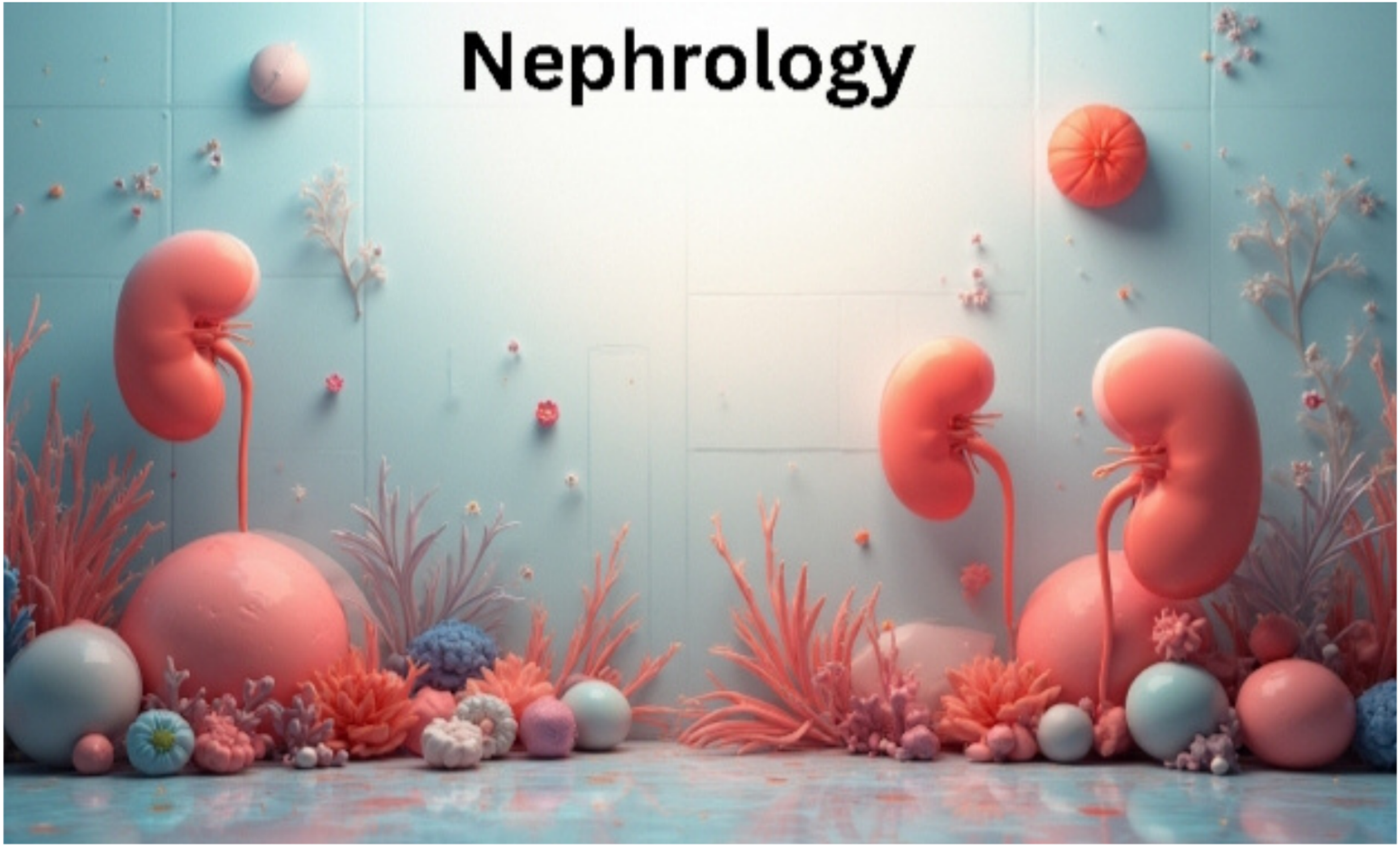

Welcome to nephrology notes by sunny[GMC VADODARA]

7874500100-whatsapp





	1] BASICS :-PODOCYTE AND GLOMERULAR STRUCTURE :-COLLAGEN STRUCTURE	**4]VASCULAR RENAL DISEASES**
	2]TYPES OF GLOMERULONEPHRITIS	5] ACUTE KIDNEY INJURY
	3]TYPES OF NEPHROTIC SYNDROME	6] ABG AND URINANALYSIS WHENEVER NEEDED DURING QUESTION SOLVING
	3]ATI	7]SOME TABULAR INFORMATION AND SOME CLINICAL QUESTIONS AHEAD

How to use?

USING THE NOTES JUST FOR THEORY LEARNING WILL BE BORING AND TIRING,,,HENCE I HAVE INCLUDED SOME CLINICAL STYLE QUESTIONS AND THE ADDITIONAL NECESSARY TOPICS NEEDED TO SOLVE THESE QUESTIONS AT THE END OF THE NOTES.

I HAVE INCLUDED ONLY SUCH QUESTIONS THAT HAVE A DIAGNOSTIC COMPONENT WITH THEM.

THIS NOTES ARE MADE FOR REFERENCE TO SOLVE SOME TYPES OF MCQS ,,,SO DONT GET BORED OFF JUST BY SEEING THE CONTENT.

Lets get started!!

PODOCYTE AND GLOMERULAR STRUCTURE

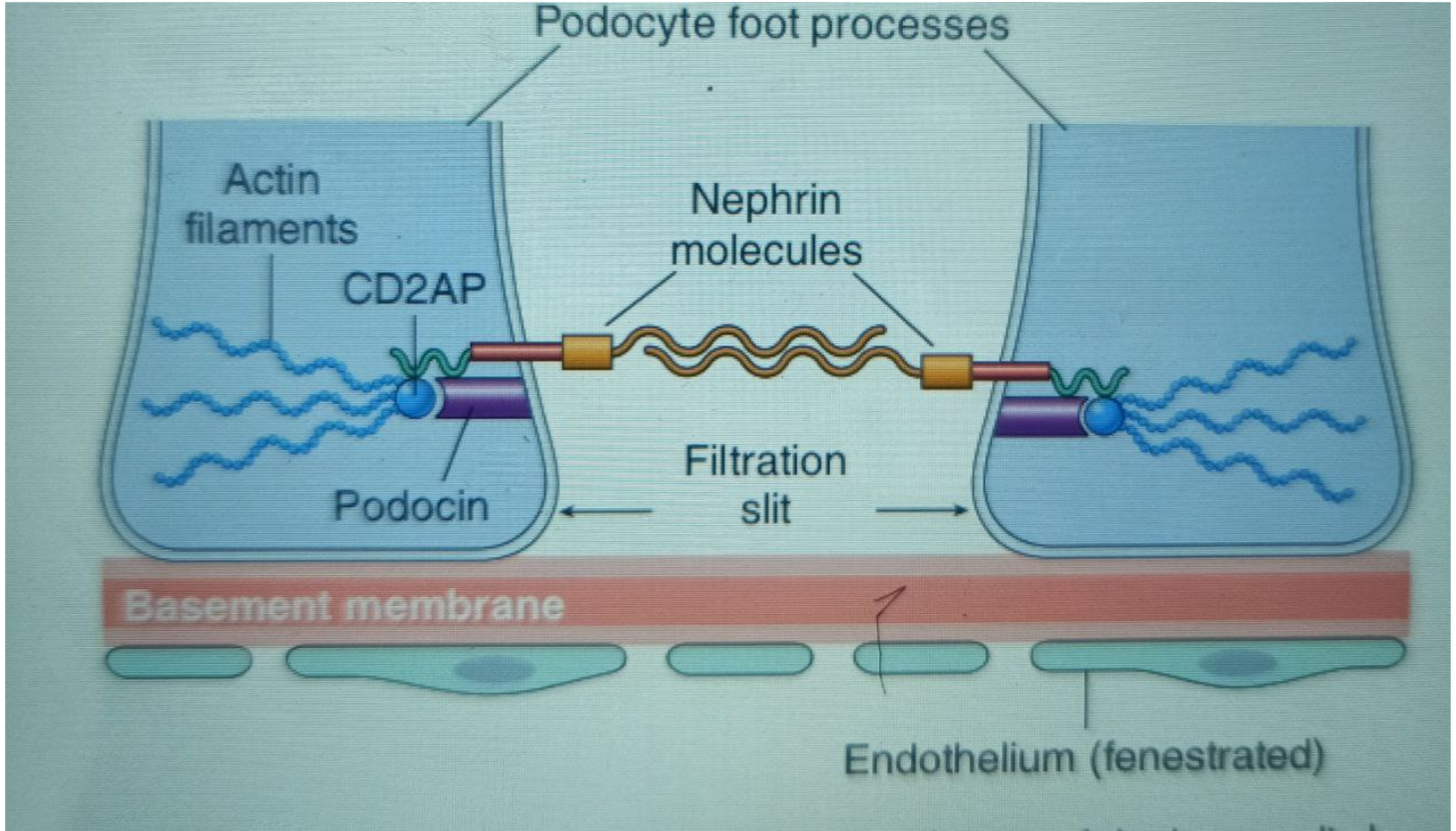

Podocytes have foot process present in lamina rara externa layer of basement layer[see previous page diagram].Gap between foot processes is known as filtration slit.Podocyte foot process form main barrier for leakage of proteins[mainly albumin].

Diaphragm:- Covers filtration slit. Made of nephrin and podocin.[see diagram]

Glomerular basement membrane

made mainly by podocyte. Three layers on electron microscopy are:-lamina densa,, lamina rara interna and lamina rara externa.

components

collagen IV,,laminin,,entactin,,fibronectin,,heparin sulphate,,perlecan. Heparin sulphate gives GBM negative charge so that albumin can’t leak.In anti gbm disease antibody is against NC1 domain of collagenIV.

Mesangium consists of mesangial matrix and mesangial cells. Mesangial cells are contractile,phagocytise,,secretive,,proliferative.

Pathological feature that indicate glomerular injury

1] hyper cellularity indicates acute injury to glomerulus. [photo ahead]

2]GBM thickening [seen in DM,MPGN,ETC]

3] Hyalinosis[deposition of eosinophilia material in extra cellular space .Represants end result of glomerular injury.

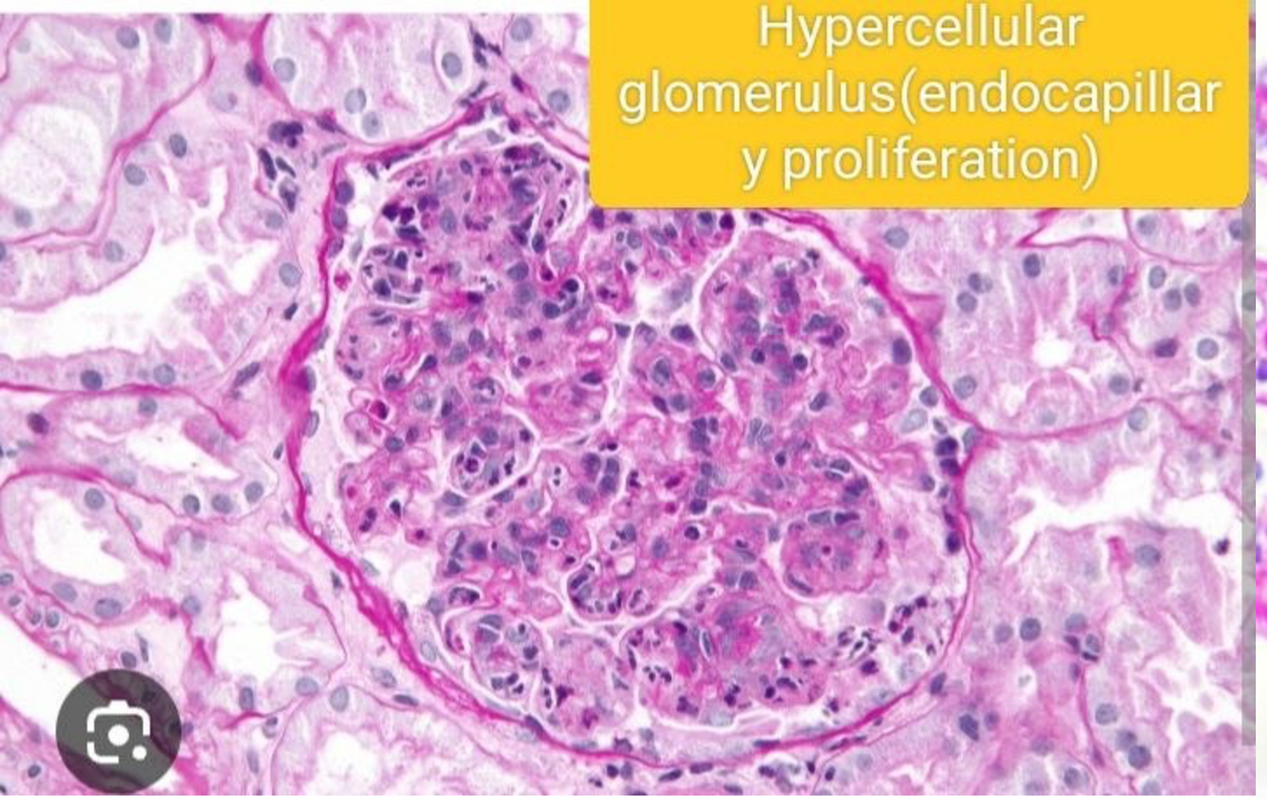
Hypercellular glomerulus(endocapillar y proliferation)

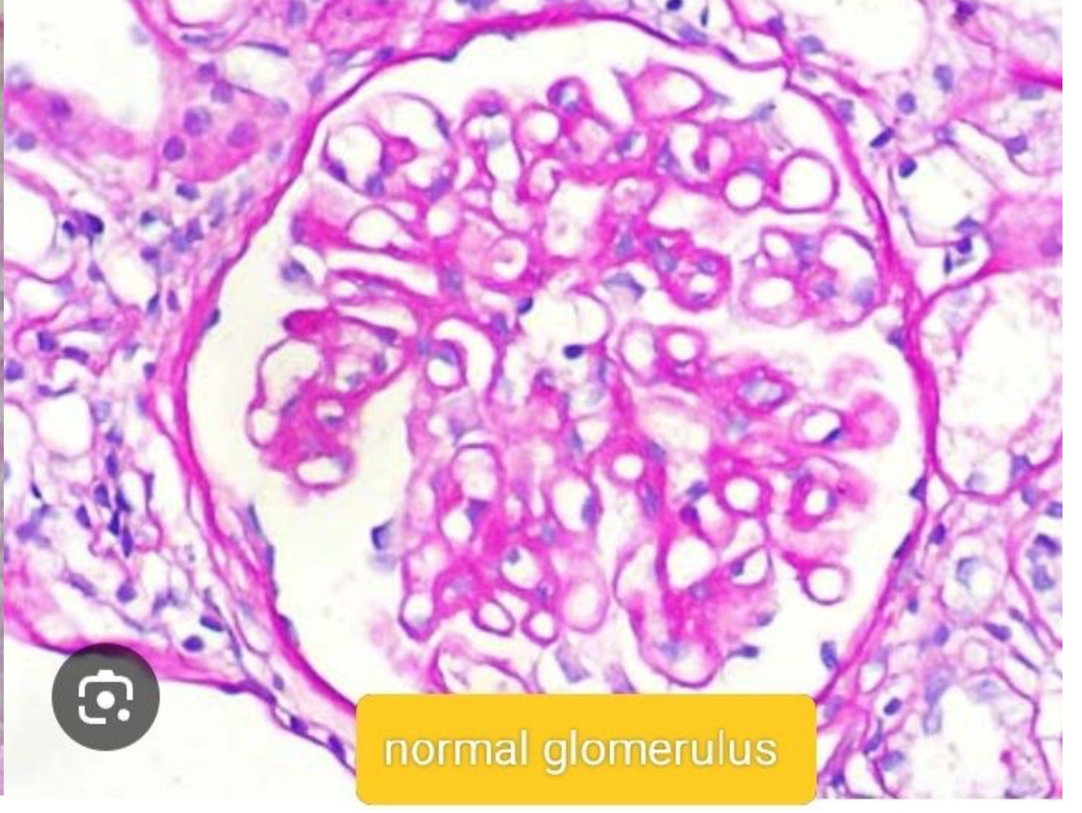
normal glomerulus

4] sclerosis:-collagen deposition around glomerular vessels or mesangium or both.Represants endothelial damage to glomerulus. Seen in Diabetic glomerulo sclerosis.

some common infections to keep in mind that cause renal diseases

syphillis,HBV,HCV,Malaria,schistosomiasis, all these cause membranous nephropathy.
HBV,HCV,HIV,Schistosomiasis also can cause MPGN TYPE I.[see glomerular diseases ahead].HIV can also cause FSGS.

PATTERN OF IMMUNE COMPLEX DEPOSITION AND THEIR DISEASES[seen under electron microscopy]

Subendothelial deposits:-early psgn,SLE nephritis,mpgn type I,,cryoglobulinemia.

subepithelial hump:- late PSGN
Subepithelial deposits:-membranous nephropathy
mesangium:-IgA nephropathy

HOW TO CONFIRM IMMUNECOMPLEX DEPOSITION?

1] IMMUNOFLOURESENCE
2] BLOOD LEVELS OF COMPLEMENT

NEXT PAGE GIVES INFORMATION ABOUT CHANGES IN BLOOD LEVELS OF VARIOUS COMPLEMENT AND THE ASSOCIATED DISEASES. INFORMATION IS GENUINE AND TAKEN FROM STANDARD BOOKS.

1]LOW C3,C4,CH50:- CLASS IV LUPUS,MPGN TYPE I,CRYOGLOBULINEMIA

2]LOW C3,NORMAL C4,LOW CH50:-PSGN,GN ASSOCIATED WITH OTHER INFECTIONS LIKE IE,HUS.

3]PLUS C3 NEPHFRITIC FACTOR:-DDD

4] HEREDITARY C2 OR C4 DEFICIENCY,,FACTOR H DEFICIENCY:-LUPUS NEPHRITIS,FAMILIAL HUS,,DDD

5]ASO TITRE WITH LOW C3 AND NORMAL C4 :- PHARYNGITIS,IMPETIGO.[PSGN]

IMMUNOFLOUROSENCE TEST.

LINEAR STAINING:-ANTI-GBM Ds

LUMPY BUMPY/STARRY SKY/GRANULAR STAINING:-ALL THE CONDITIONS THAT I MENTIONED IN SUBEPITHELIAL HUMP,SUBEPITHELIAL DEPOSITS SUBENDOTHELIAL DEPOSITS, GIVE GRANULAR APPEARANCE.

GRANULAR PATTERN OF DEPOSITION,,IN WHICH DEPOSITION IS ALONG CAPILLARY WALL. SEE THE CARTOON DIAGRAM FIRST AND THEN THE IF IMAGE.

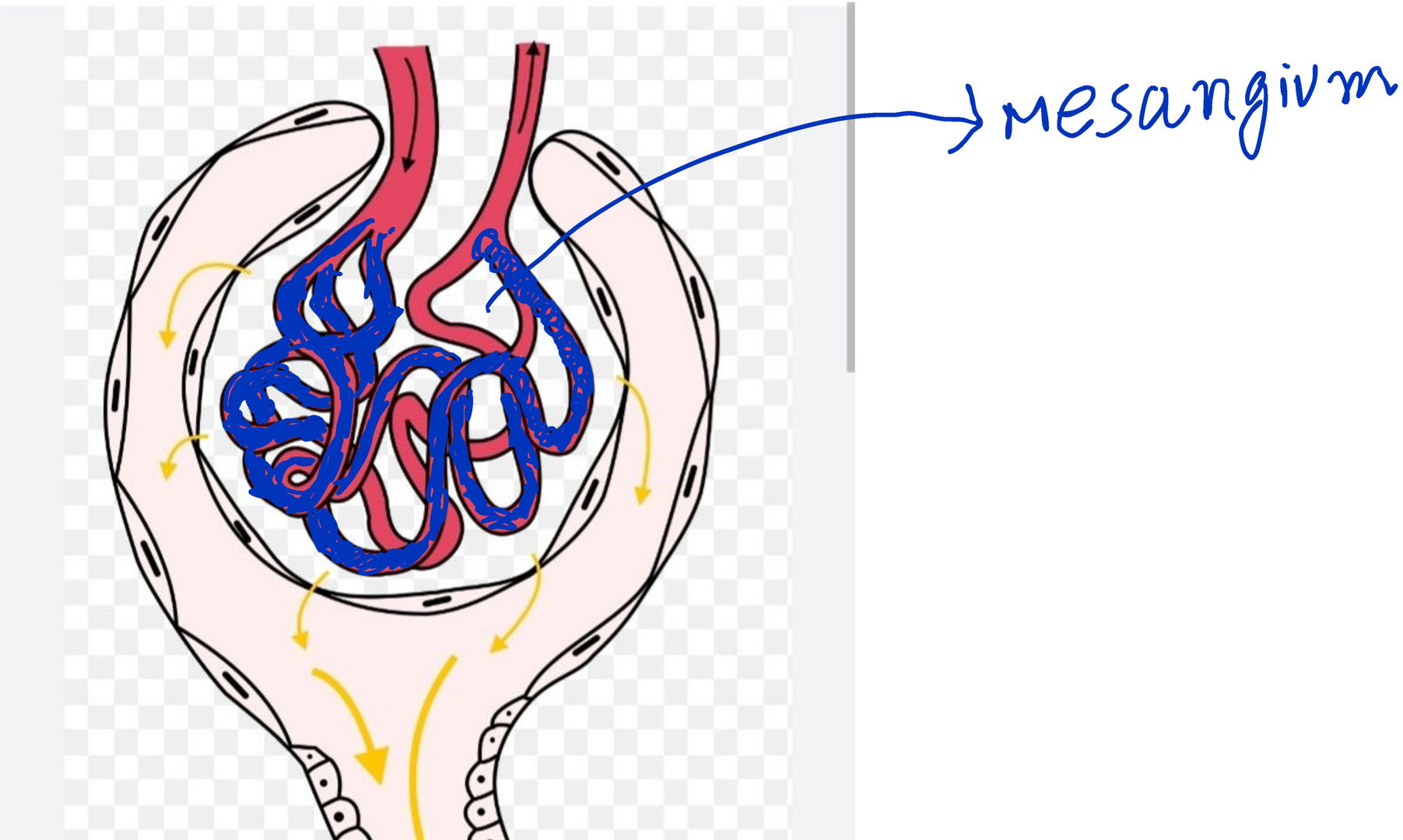

GRANULAR IF

Blue lines = capillaries

Red = Mesangium

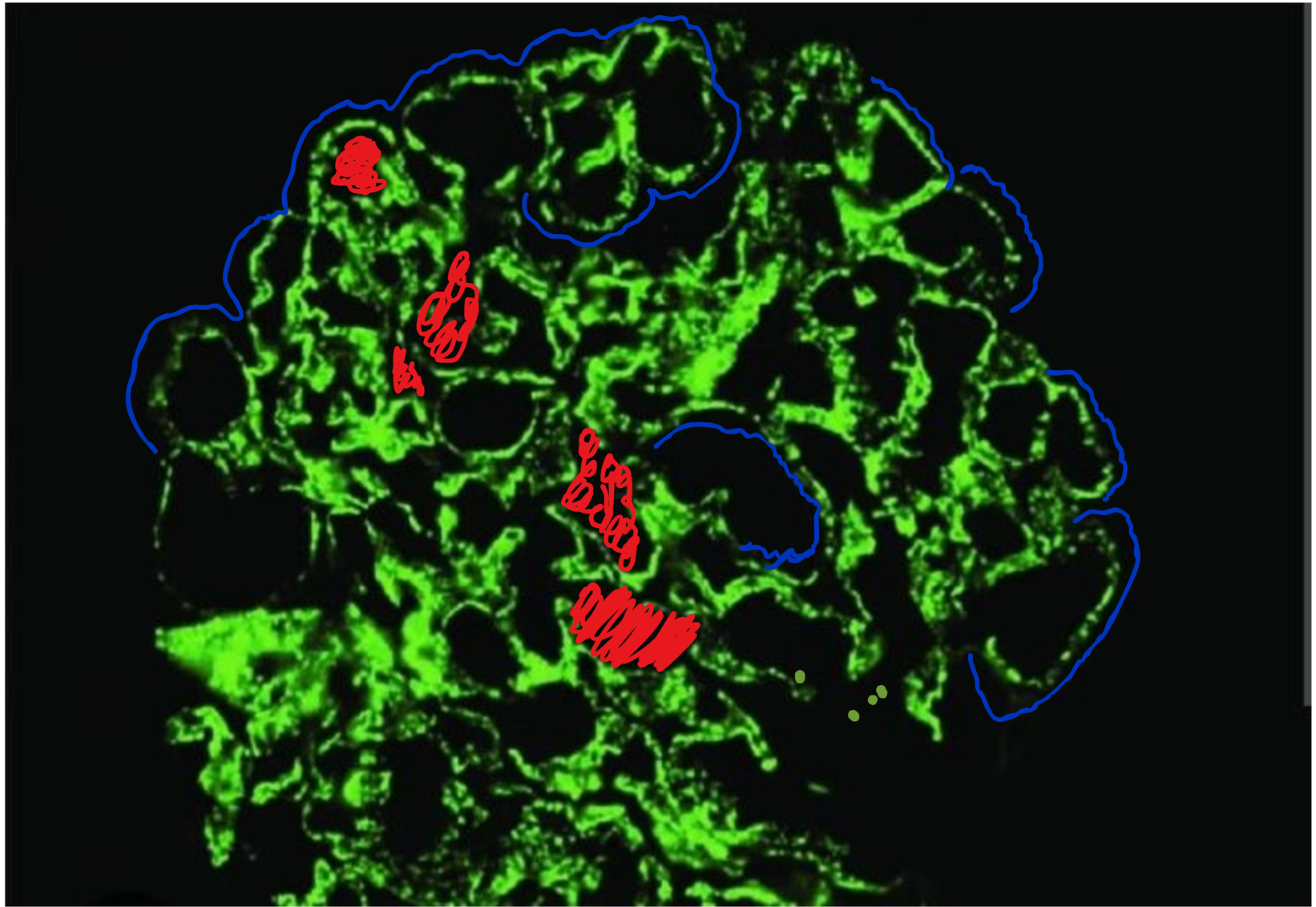

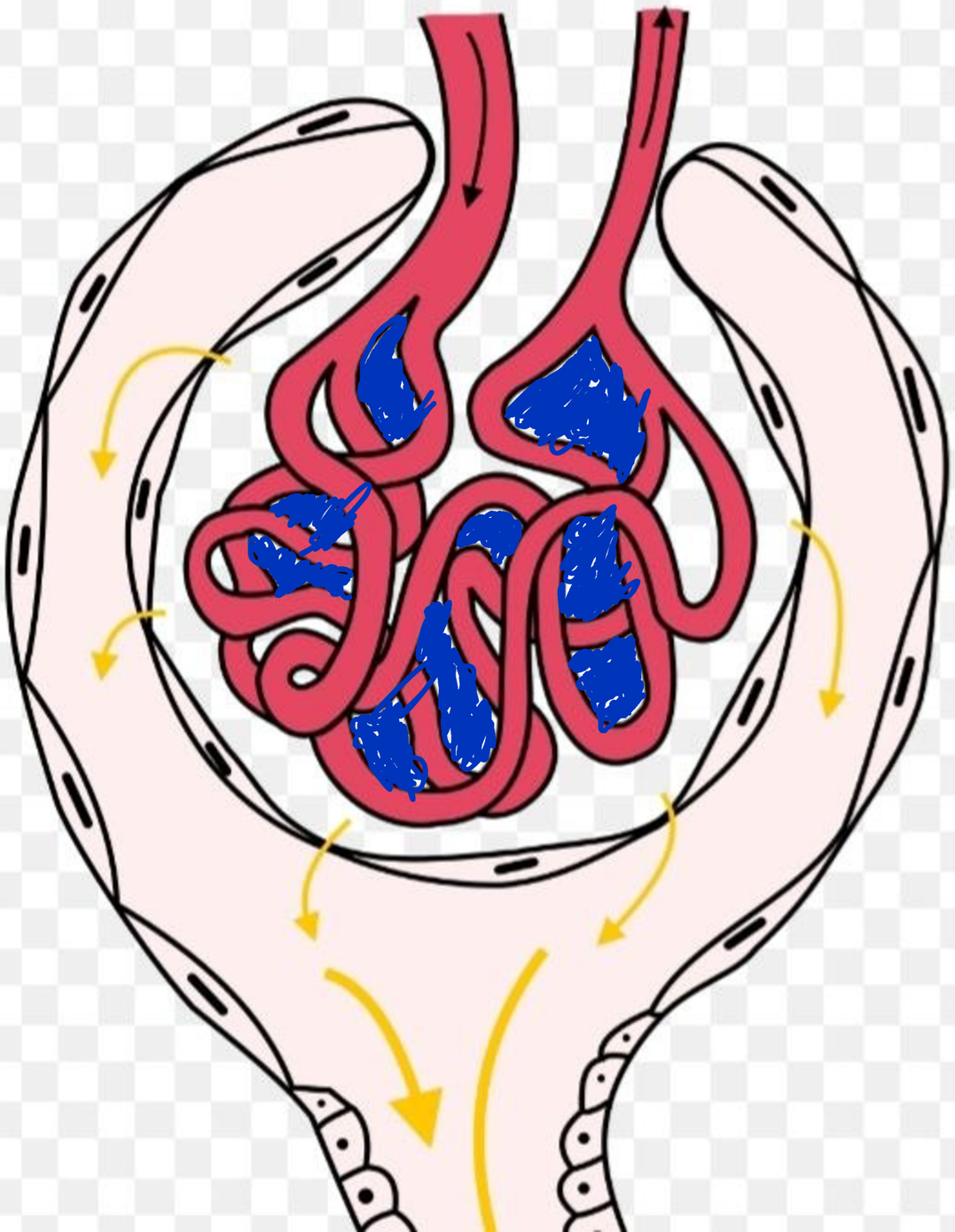

MESANGIAL DEPOSITION IF

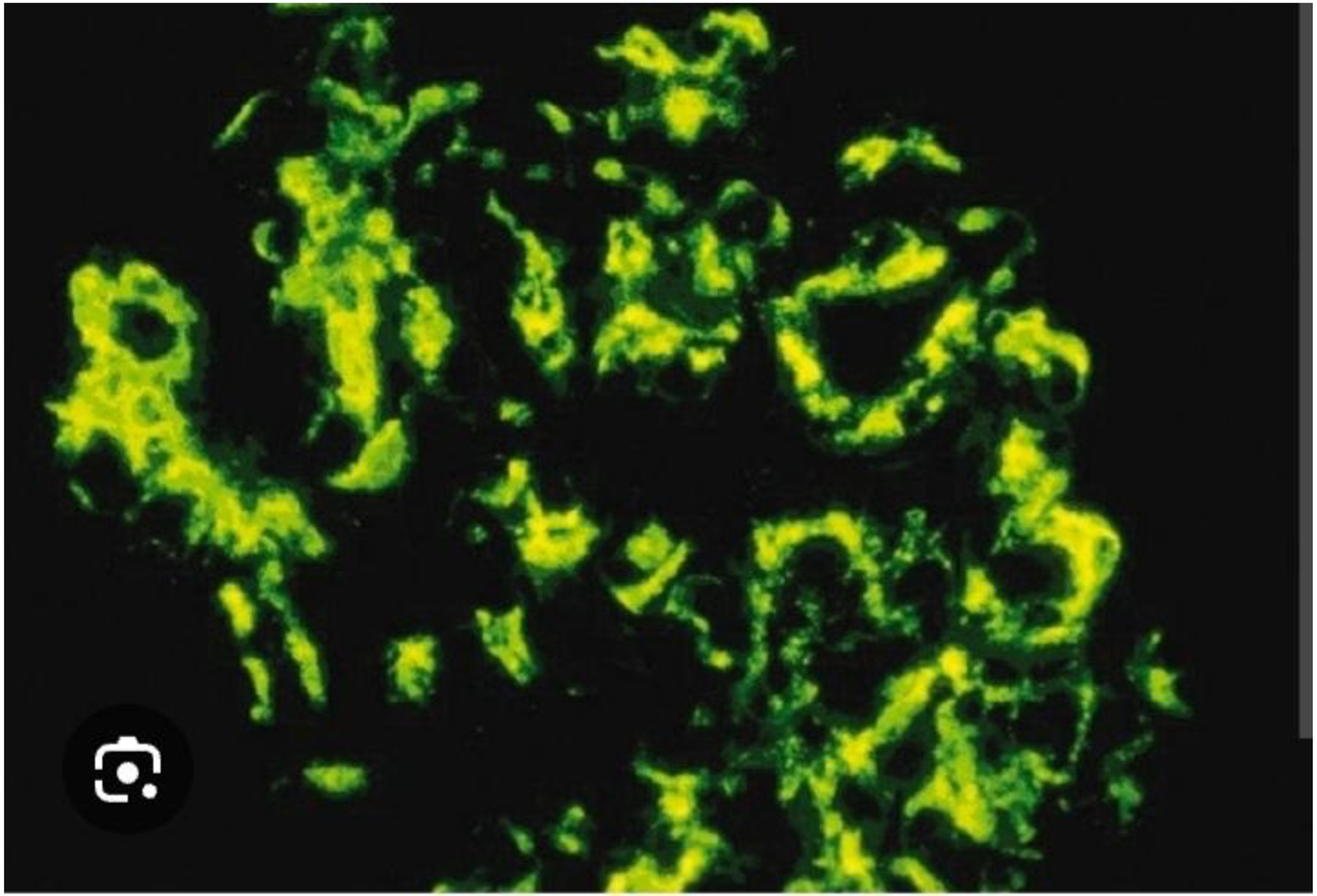

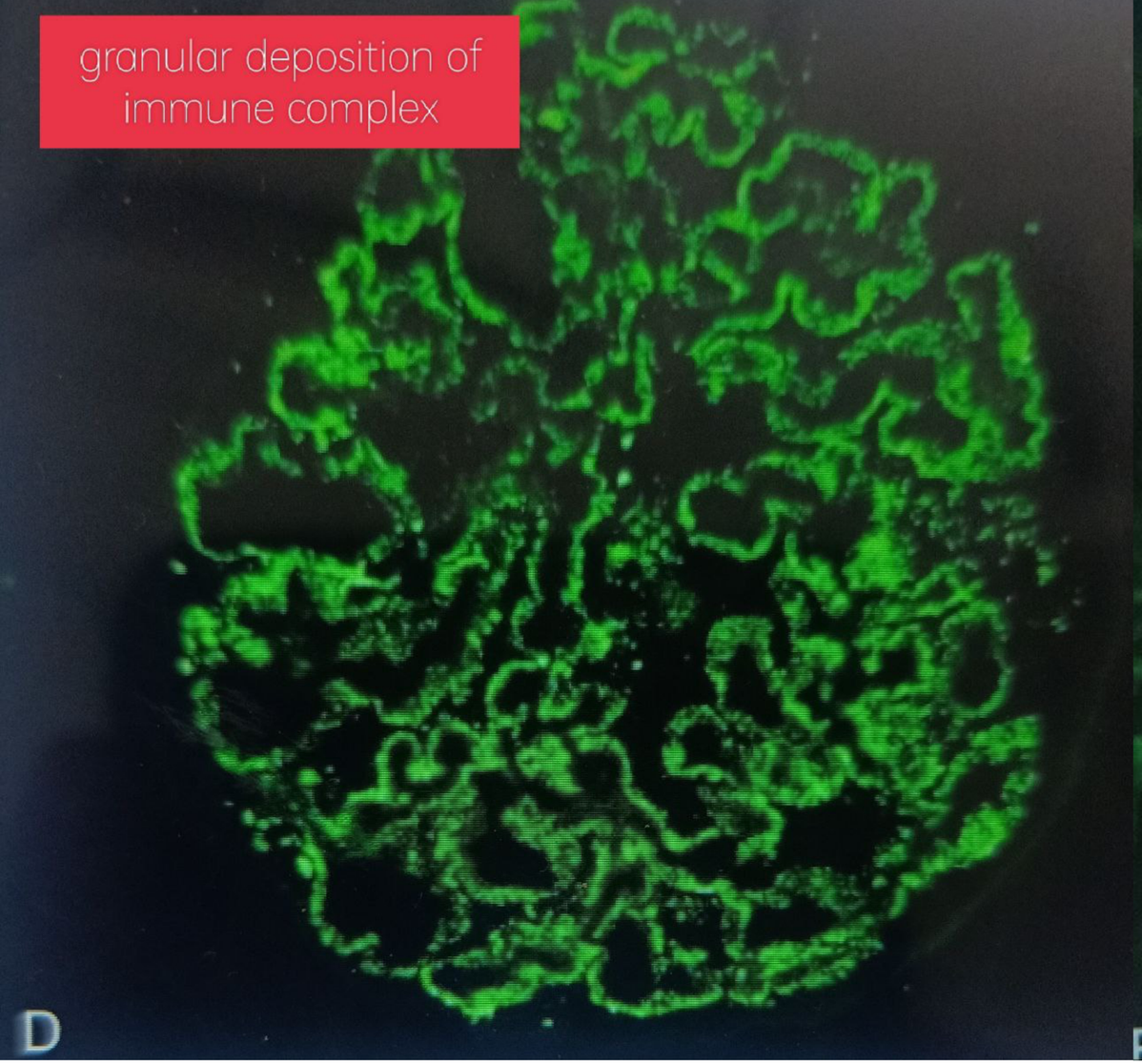
granular deposition of
immune complex
D

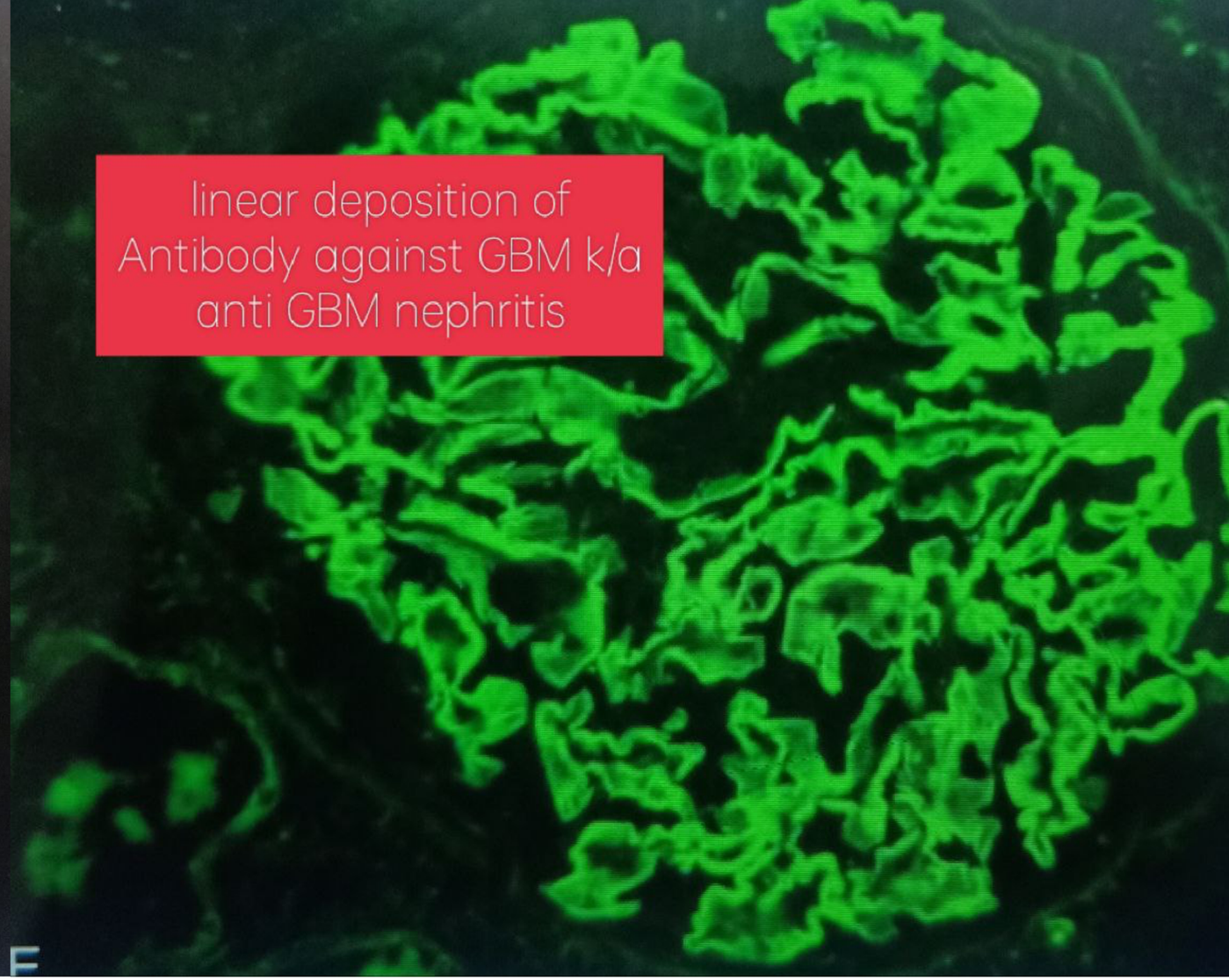
linear deposition of
Antibody against GBM k/a
anti GBM nephritis
E

LETS GO WITH

NEPHRITIC SYNDROME

SOME TERMS

1) NEPHRITIC syndrome

2) CHRONIC GN

3) RPGN

1]NEPHRITIC SYNDROME:-RED CELL CAST,PROTEINURIA LESS THEN 3G/DAY,,EDEMA,,HTN WHICH IS ABRUPT ONSET AND IS SELF LIMITED.

2]RPGN:- RENAL FAILURE OVER DAYS TO WEEKS ,,PROTEINURIA LESS THEN 3G/DAY,,RED CELL CAST,,OFTEN NORMAL BLOOD PRESSURE.

3]CHRONIC GN:-HTN,,PROTEINURIA MORE THEN 3G/DAY,,SHRUNKEN ,,SMOOTH KIDNEYS.

CAUSES OF GTN

1]PSGN(ACUTE PROLIFERATIVE GN)

2]RPGN(CRESCENTIC GN)

3]IGA NEPHROPATHY

4]ANTI GBM GN

5]MPGN TYPE 1

6]ALPORT SYNDROME AND BENIGN FAMILIAL HEMATURIA.

INDICATION FOR KIDNEY BIOPSY

Table 29.1 Indications for Kidney Biopsy

- Significant proteinuria (>1 g/day or protein to creatinine ratio > 100 mg/mmol or > 1 g/g)
- Microscopic hematuria with any degree of proteinuria
- Unexplained renal impairment (native or transplanted kidney)
- Renal manifestations of systemic disease

PSGN

SOME FACTS:- IMPETIGO IS MORE LIKELY TO CAUSE SGN AS COMPARED TO SORE THROAT.AGE FACTOR IS 6-10 YEARS.DUE TO ANTIBODIES AGAINST M PROTEIN OR SPE-B.THESE IMMUNE COMPLEX GET DEPOSITED IN GLOMERULI AND CAUSE NEPHRITIC SYNDROME WHICH CAN PROCEED TO RPGN.STRAINS OF STREPTOCOCCI[GROUP A] CAUSING ARE 1,4,2;6,25,49,51

CLINICAL FEATURES:-POST 1-4 WEEKS IMPETIGO THERE OCCURS OLIGURIA,,HEMATURIA,,HTN,,PERIORBITAL EDEMA.

DIAGNOSIS:-

1]LM:- ENDOCAPILLARY PROLIFERATION

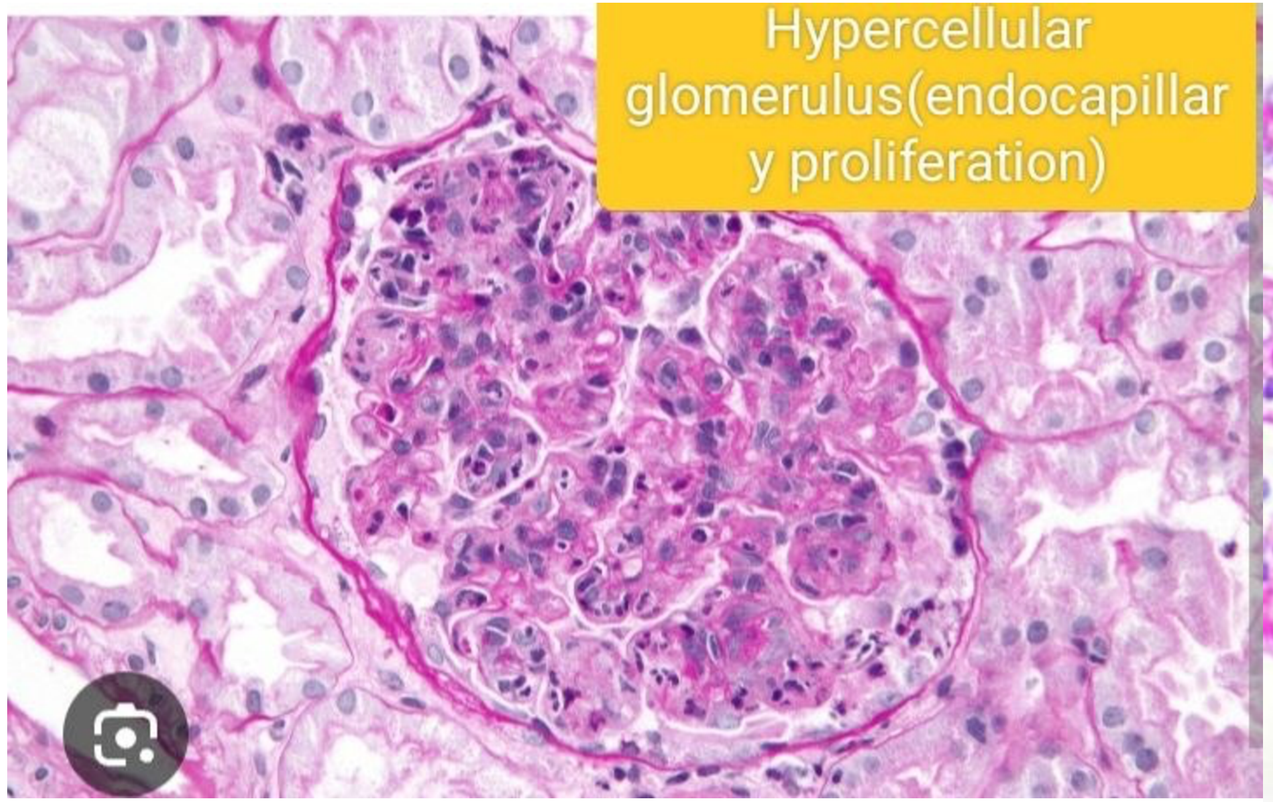

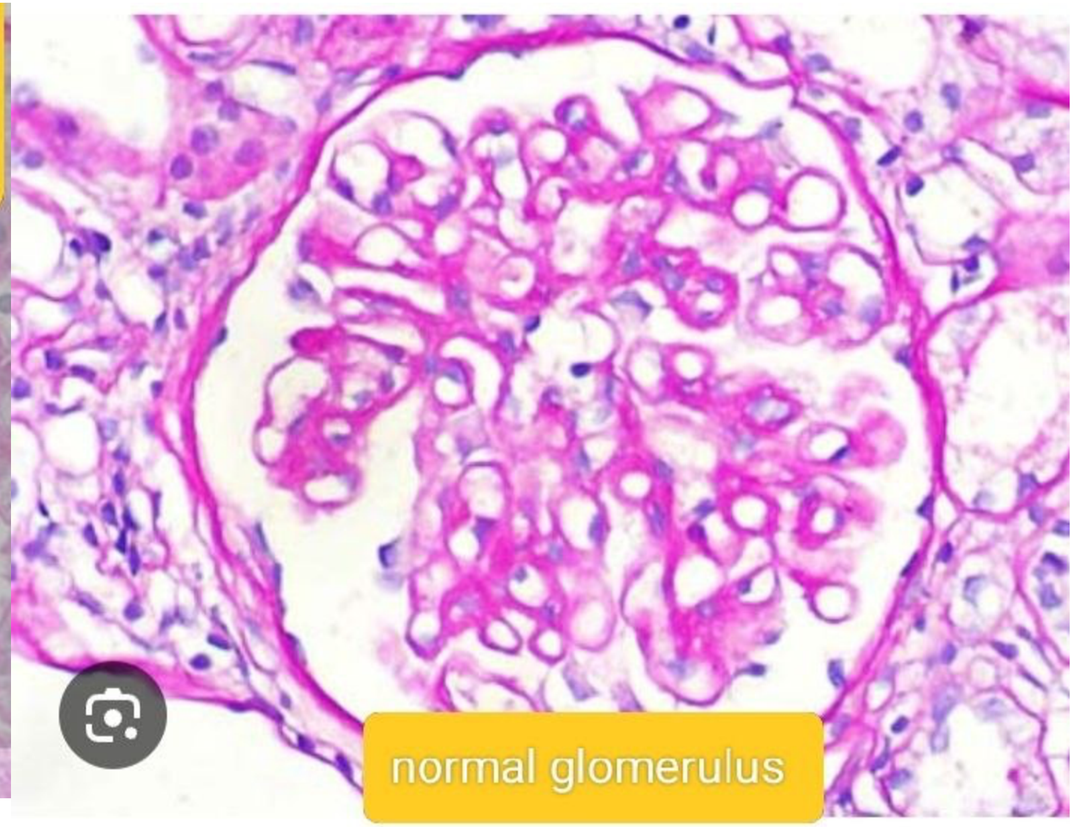

FLOURESCENT MICROSCOPY

GRANULAR PATTERN/STARRY SKY PATTERN FOR IgG AND C3

ELECTRON MICROSCOPY SUBEPITHELIAL HUMP.

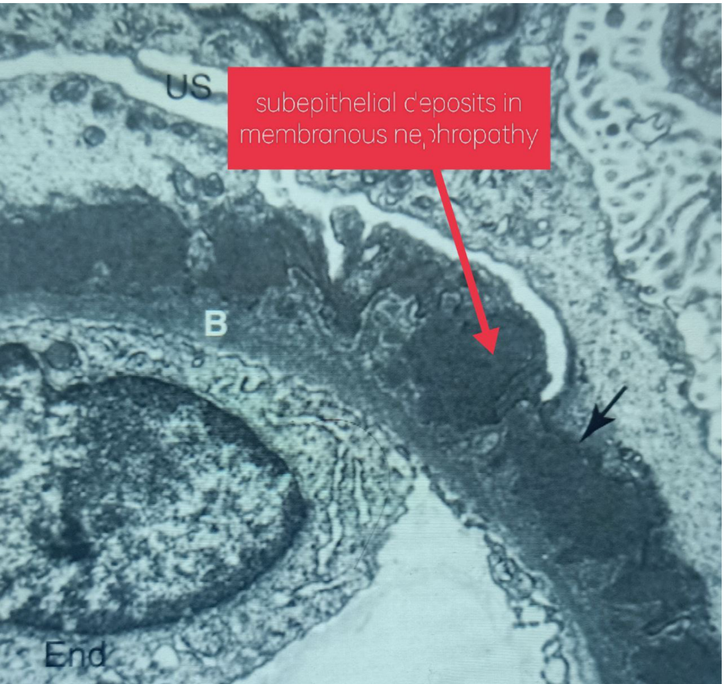

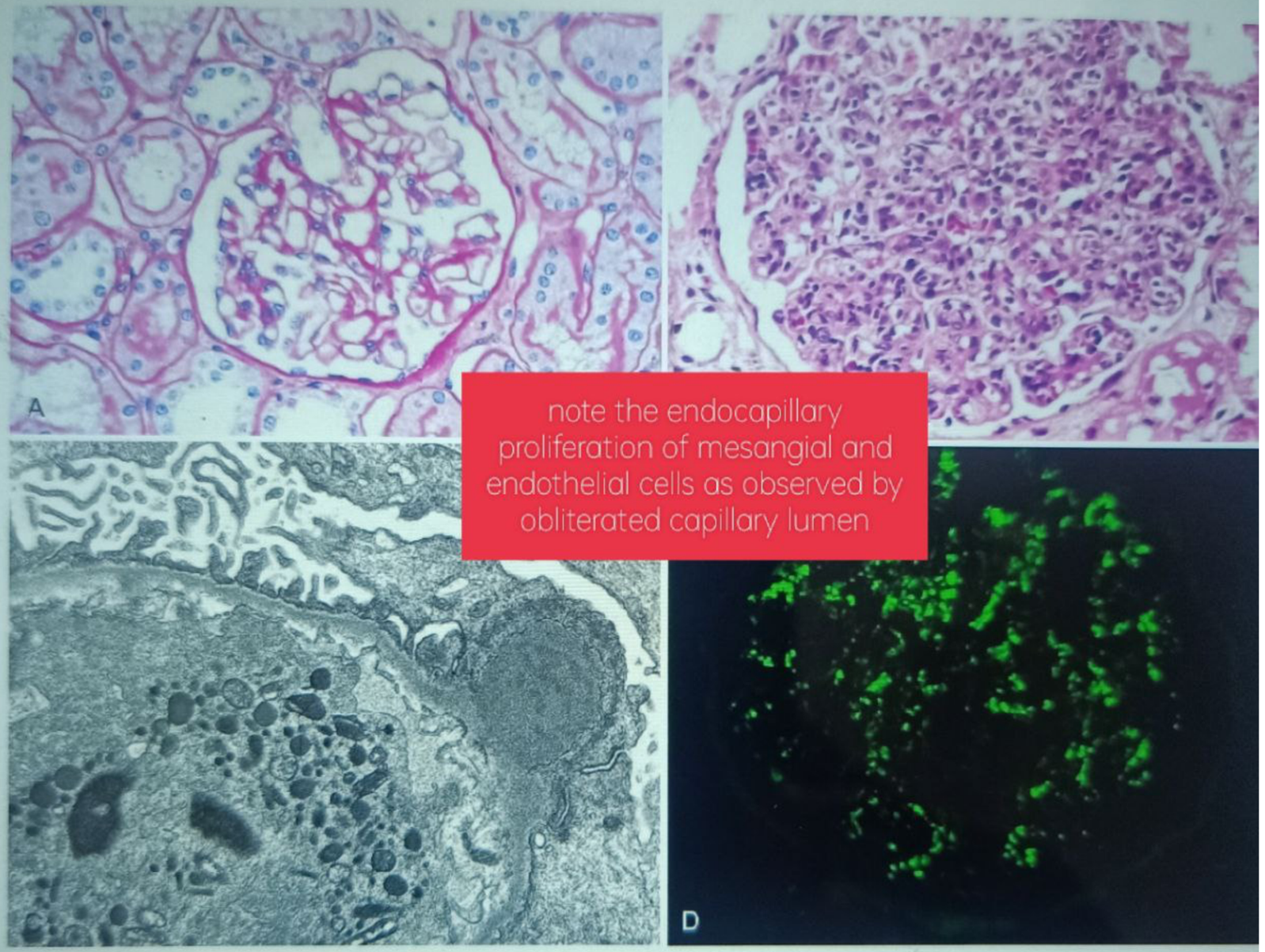

note the endocapillary proliferation of mesangial and endothelial cells as observed by obliterated capillary lumen

Figure 20.8 Acute proliferative glomerulonephritis. (A) Normal glomerulus. (B) Glomerular hypercellularity is due to intracapillary leukocytes and proliferation of intrinsic glomerular cells. (C) Typical electron-dense subepithelial "hump" and a neutrophil in the lumen. (D) Immunofluorescent stain demonstrates discrete, coarsely granular deposits of complement protein C3 (stain for IgG was similar), corresponding to "humps" illustrated in part (A–C, Courtesy Dr. H. Rennke, Brigham and Women's Hospital, Boston, Mass. *D*, Courtesy D. J. Kowalewska, Cedars-Sinai Medical Center, Los Angeles, Calif.)

BLOOD FINDINGS:-ANTIDNAse Ab FOR RETROSPECTIVE DIAGNOSIS

:-ASO TITRE

:-LOW C3 LEVELS

SOME TERMS TO BE UNDERSTOOD.

1]ACUTE RENAL FAILURE:-SERUMU CREATININE INCREASE OF MORE THEN 0.3 MG/DL DEVELOPING OVER LESS THEN 48 HOURS OR AN INCREASE OF MORE THEN 50 % OVER LESS THEN 7 DAYS

:- DECRESE IN URINE OUTPUT TO LESS THEN 0.5 ml/KG/Hr for more then 6 hours.

2]RAPIDLY PROGRESSIVE RENAL FAILURE:-IN CONTRAST TO ACUTE RENAL FAILURE,, THIS ENTITY HAS A DECLINE IN KIDNEY FUCTION OVER DAYS TO WEEKS.

3] RPGN:-IF RAPIDLY PROGRESSIVE RENAL FAILURE IS CAUSED BY GLOMERULONEPHRITIS,, ITS KNOWN AS RPGN. IF RPGN ON KIDNEY BIOPSY IS FOUND TO HAVE CRESCENTS THEN ITS KNOWN AS CRESCENTIC GLOMERULONEPHRITIS.

TYPES OF RPGN

TYPE 1 :-ANTI GBM{LINEAR PEATTERN ON IF]

TYPE 2:-IMMUNE COMPLEX MEDIATED(granular pattern on IF)

A) PSGN,,HSP(IgA VASCULITIS),,IgA NEPHROPATY

TYPE 3]PAUCIIMMUNE(NO PATTERN,, IF NORMAL):-

ANCA POSITIVE,, SEEN IN MICROSCOPIC POLYANGITTIS ,,WEGNER GRANULOMATOSIS AND CHURG STRAUSS.

BOX 2 Diseases associated with crescentic glomerulonephritis (GN).

Primary glomerular diseases:

- Idiopathic crescentic GN
- Superimposed on other primary glomerular diseases:
  - Mesangiocapillary GN, IgA nephropathy, membranous GN

Associated with infections:

- PSGN, infective endocarditis, visceral abscess

Associated with drugs:

- Penicillamine, rifampicin

Associated with multisystem diseases:

- Systemic lupus erythematosus
- Goodpasture's disease
- Cryoglobulinemia
- Vasculitides:
  - Granulomatosis with polyangiitis
  - Eosinophilic Granulomatosis with polyangiitis

Biopsy of CRESCENTIC GN

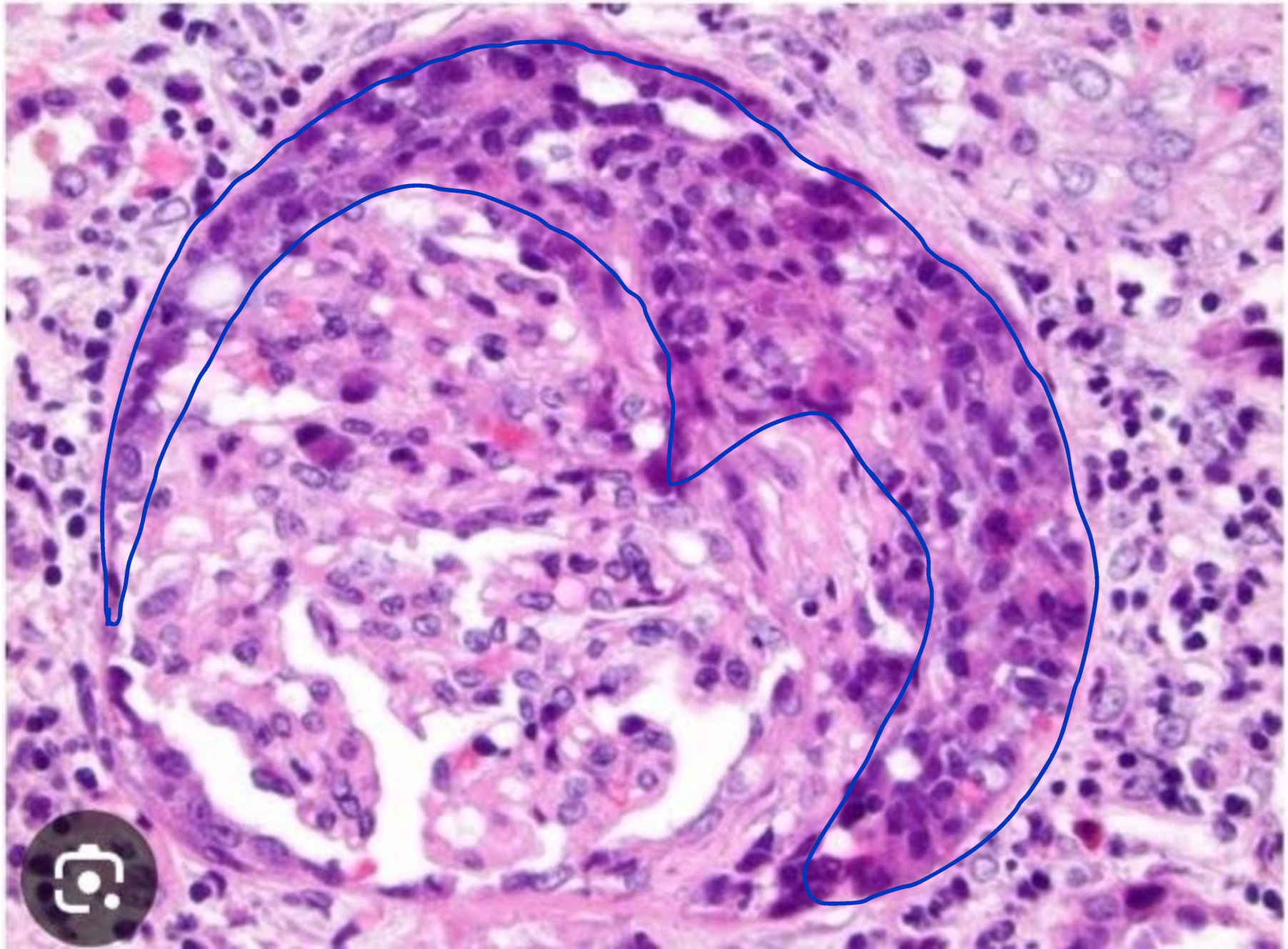

TYPE I RPGN

SOME TERMS

1] GOODPASTURE DISEASE:-ANTIBODIES AGAINST ALPHA3IVNC1 AND MAY INCLUDE RPGN OR ALVEOLAR HAEMORRHAGE OR BOTH.

2] GOOD PASTURE SYNDROME:-RPGN WITH ALVEOLAR HAEMORRHAGE.

IN ANTI GBM DISEASE THE ANTIGEN IS AGAINST ALPHA3IVNC1 OF COLLAGEN. THE POINT IS THAT THE ALPHA3 CHAIN IS PRESENT IN BASEMENT MEMBRANE OF OTHER TISSUE LIKE LUNGS,BRUSCH MEMBRANE,,CHOROID PLEXUS,,COCHLEA AND SOME ENDOCRINE ORGANS.

LETS CONSIDER A SPECIAL SITUATION. A PATIENT OF ALPORT SYNDROME UNDERGOES RENAL TRANSPLANT FOR FIRST TIME.THE KIDNEY OF A PATIENT WITH ALPORT SYNDROME WILL NOT HAVE A NORMAL GBM COLLAGEN AS ONE OF THE ALPHA CHAINS [MOSTLY APLHA 5] WILL BE ABSENT. SINCE ALPHA CHAINS 3,4,5 ARE ASSEMBLED WITH EACH OTHER,, ABSCENCE OF ALPHA 5 CHAIN WILL CAUSE ALL THE THREE CHAINS TO BE DISASSOCIATED AND THERE WILL BE ABSCENCE OF ALL THE THREE ALPHA CHAINS 3,4,5.

SO A PATIENT OF ALPORT SYNDROME HAD NEVER HAD ALPHA CHAINS IN THE GBM,, SO UNDERSTAND THIS IN A SIMPLE WAY, SINCE THE KIDNEY OF Pt OF ALPORT SYNDROME DONT HAVE ALPHA CHAINS,, THE BODY DOES NOT KNOWS WHAT ALPHA CHAINS ACTUALLY ARE DUE TO TOTAL LACK OF EXPOSURE TO ALPHA CHAINS.HENCE WHEN THE KIDNEY OF Pt OF ALPORT SYNDROME FINALLY REACHES ESKD,,THE Pt OF ALPORT SYNDROME NEEDS TRANSPLANTATION WITH A HEALTHY KIDNEY THAT CONTAINS ALL THE THREE ALPHA CHAINS IN THE GBM.

THESE ALPHA CHAINS COMING FROM THE HEALTHY KIDNEY,, WILL BE COMPLETELY FOREIGN TO THE Pt OF ALPORT SYNDROME AS THE BODY OF Pt OF ALPORT SYNDROME WAS NEVER HAVING ALPHA CHAINS.SO THE BODY OF ALPORT SYNDROME PT WILL GENERATE ANTIBODY AGAINST ALPHA 5 CHAINS,, WHEN IT RECIEVES THE HEALTHY DONOR KIDNEY THAT CONTAINS THE ALPHA CHAINS.THESE ANTIBODY WILL BIND TO ALPHA 5 CHAIN IN THE GBM OF DONOR KIDNEY,HENCE PRODUCING LINEAR PATTERN ON IMMUNOFLUORESCENCE.

THERE IS SOME ADDITIONAL INFORMATION ON THIS CONCEPT,, BUT I WILL PROVIDE IT DURING SOLVING QUESTIONS IN ORDER TO PRESERVE THE SUSPENSE.

SINCE ALPHA CHAINS ARE ALSO PRESENT IN COCHLEA (ALPHA 3,4,5) THE ANTI GBM ANTIBODIES ALSO REACT TO COCHLEA CAUSING NERVE DEFFNESS IN PATIENT OF ALPORT SYNDROME.

CAUSES OF LUNG HAEMORRHAGE ASSOCIATED WITH SYSTEMIC VASCULITIS.

BOX 25.4 Causes of Lung Hemorrhage and Rapidly Progressive Glomerulonephritis

Diseases Associated With Antibodies to the GBM (20%–40% of Cases)

- Goodpasture disease (spontaneous anti-GBM disease)

Diseases Associated With Systemic Vasculitis (60%–80% of Cases)

- Granulomatosis with polyangiitis (common)
- Microscopic polyangiitis
- Systemic lupus erythematosus
- Eosinophilic granulomatosis with polyangiitis (Churg-Strauss)
- IgA vasculitis (Henoch-Schönlein purpura)
- Henoch-Schönlein purpura
- Behçet syndrome
- Essential mixed cryoglobulinemia
- Rheumatoid vasculitis
- Drugs: Penicillamine, hydralazine, propylthiouracil

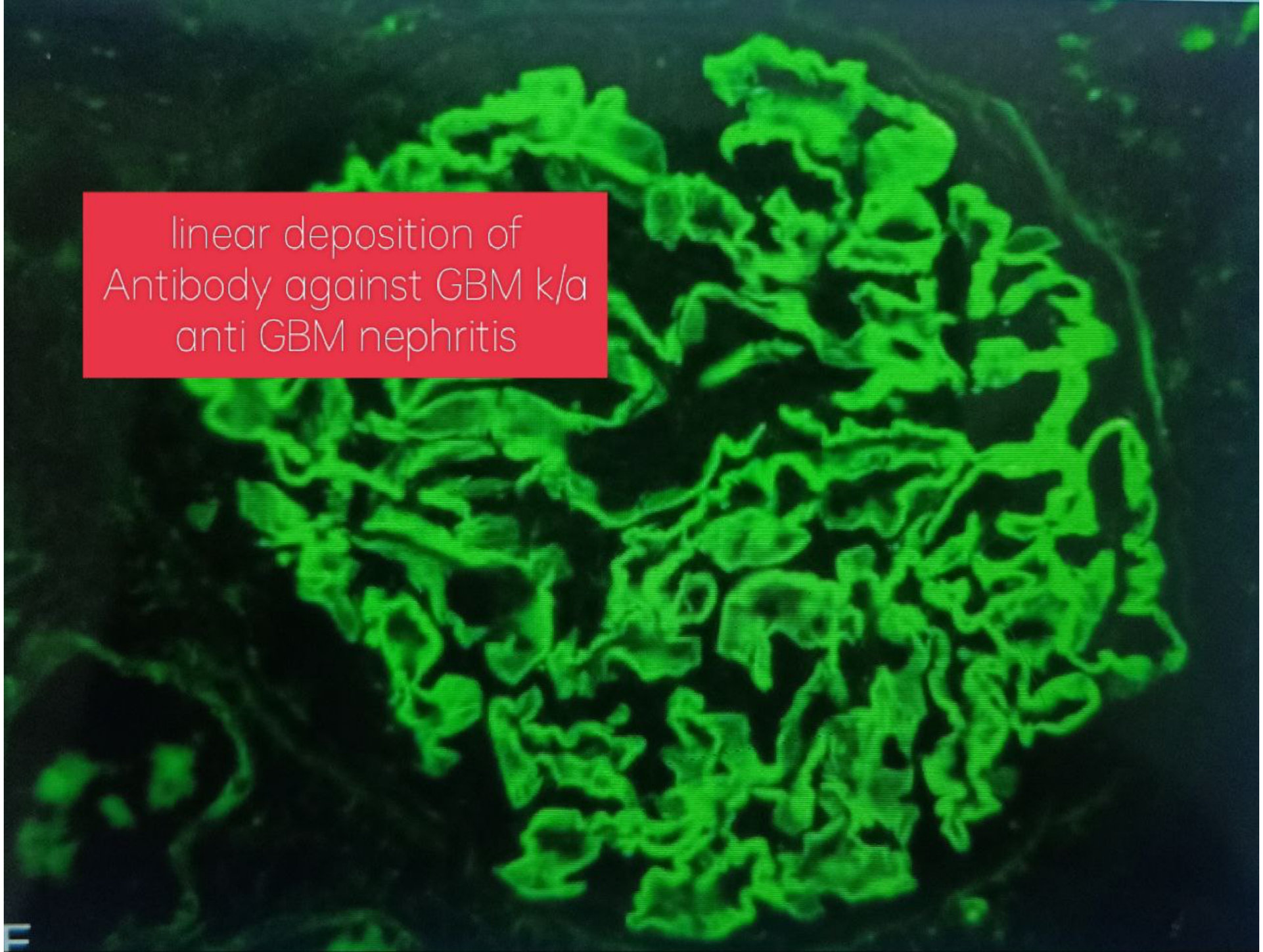
linear deposition of
Antibody against GBM k/a
anti GBM nephritis

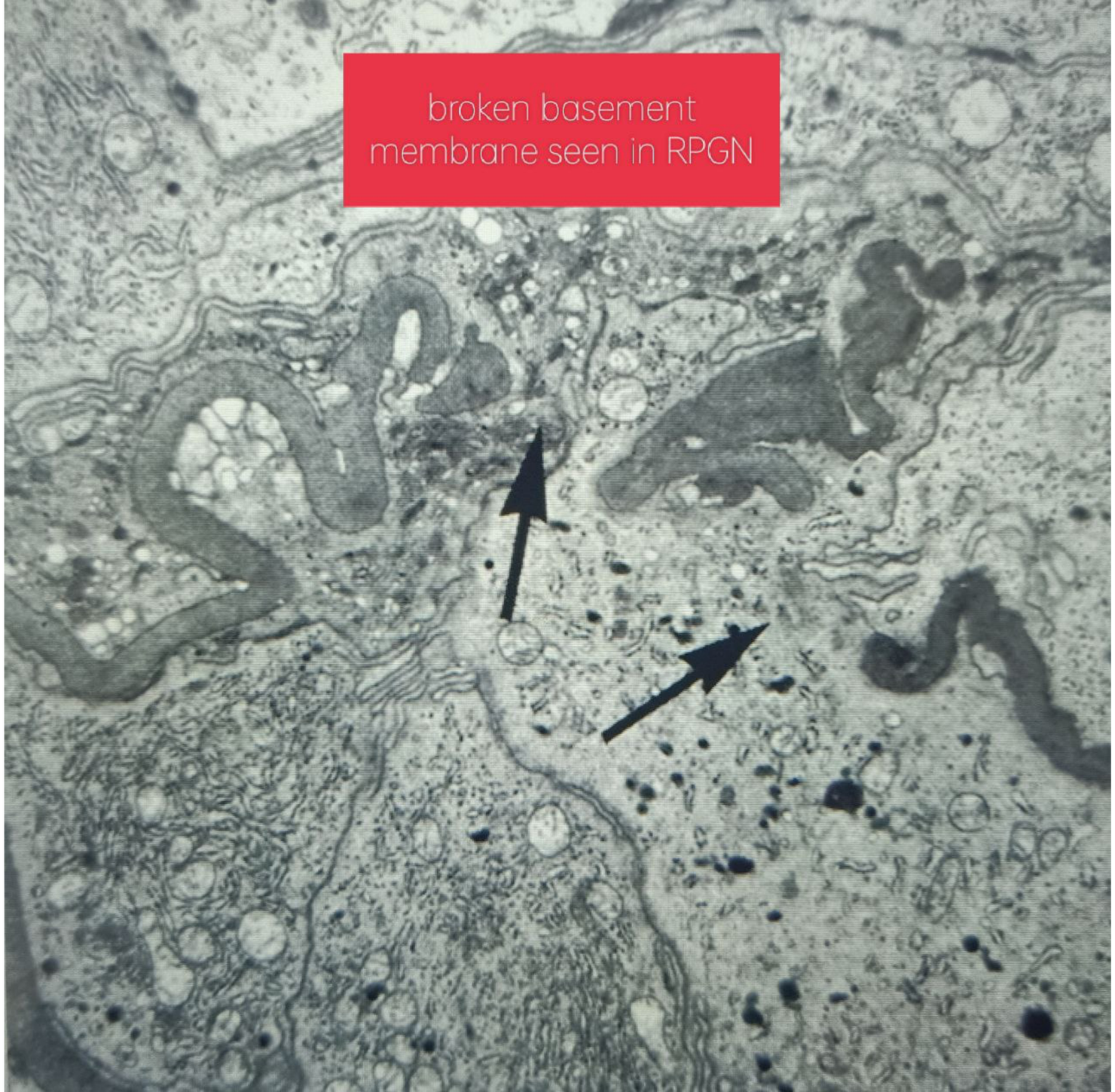
broken basement
membrane seen in RPGN

TYPE 2 RPGN

1]LATE PSGN

2]HENOCH SCHONLEIN PURPURA

3]IgA nephropathy

4]SYSTEMIC LUPUS ERYTHEMATOSUS

PSGN IS COVERED.

HENOSCH SCHONLEIN PÚRPURA

ALSO KNOEN AS IGA VASCULITIS(NOT IGA NEPHROPATHY)

SEEN IN CHILDREN,ADULT.

DRUGS,URTI,VACCINATION CAUSES IMMUNE COMPLEX FORMATION THAT GET DEPOSITED IN JOINT(ARTHRALGIA),,GUT VESSELS(ABDOMINAL PAIN),,CUTANEOUS VESSELS(ALMOST EVRY TIME,,CAUSES PALPABLE PÚRPURA ON BUTTOCK,EXTENSOR ASPECT OF LOWER LIMB),,MAY GET DEPOSITED IN GLOMERULUR MESANGIUM(CAUSES IgA NEPHROPATHY IN ADULTS KNOWN AS BERGER DISEASE,,OCCURS IN ADULT HSP)

Henosch schonlein purpura

IgA NEPHROPATHY

ALSO KNOWN AS BERGER DISEASE

MOST COMMON CAUSE OF GLOMERULONEPHRITIS WORLD WIDE.MOST COMMON CAUSE OF GROSS OR MICROSCOPIC HEMATURIA.

HINTS TOWARDS DIAGNOSIS OF IgA NEPHROPATHY

RECURRENT HEMATURIA,,MAY BE FAMILIAL,,FOLLOWS A URTI,,GIT,,UTI INFECTION.

ASSOCIATED WITH LIVER DISEASE,CELIAC DISEASE,ANKYLOSING SPONDYLITIS.

U WILL UNDERSTAND THESE DISEASE ASSOCIATIONS ONLY WHEN U HAVE GONE THROUGH MUCH ASPECT OF MEDICINE.

DIAGNOSIS

IMMUNOFLOURESCENCE:-IgA or IgA-IgG DEPOSITS IN MESANGIUM. GRANULAR PATTERN

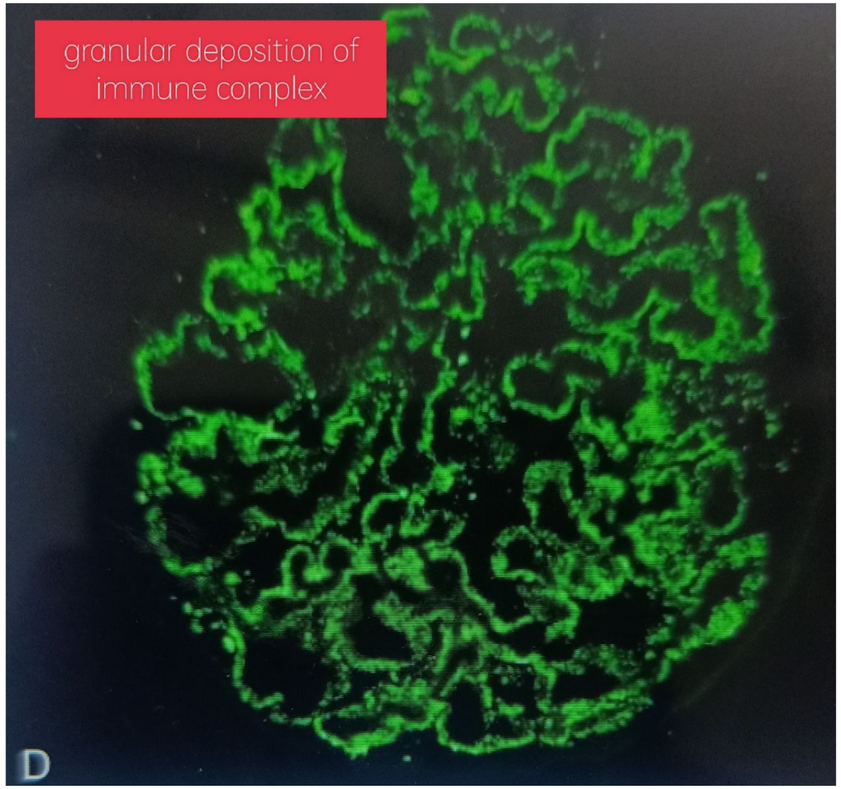

LM FEATURES:-SCLEROSIS SECONDARY TO HEALING OF GLOMERULUR LESIONS AND MESANGIAL WIDENING.

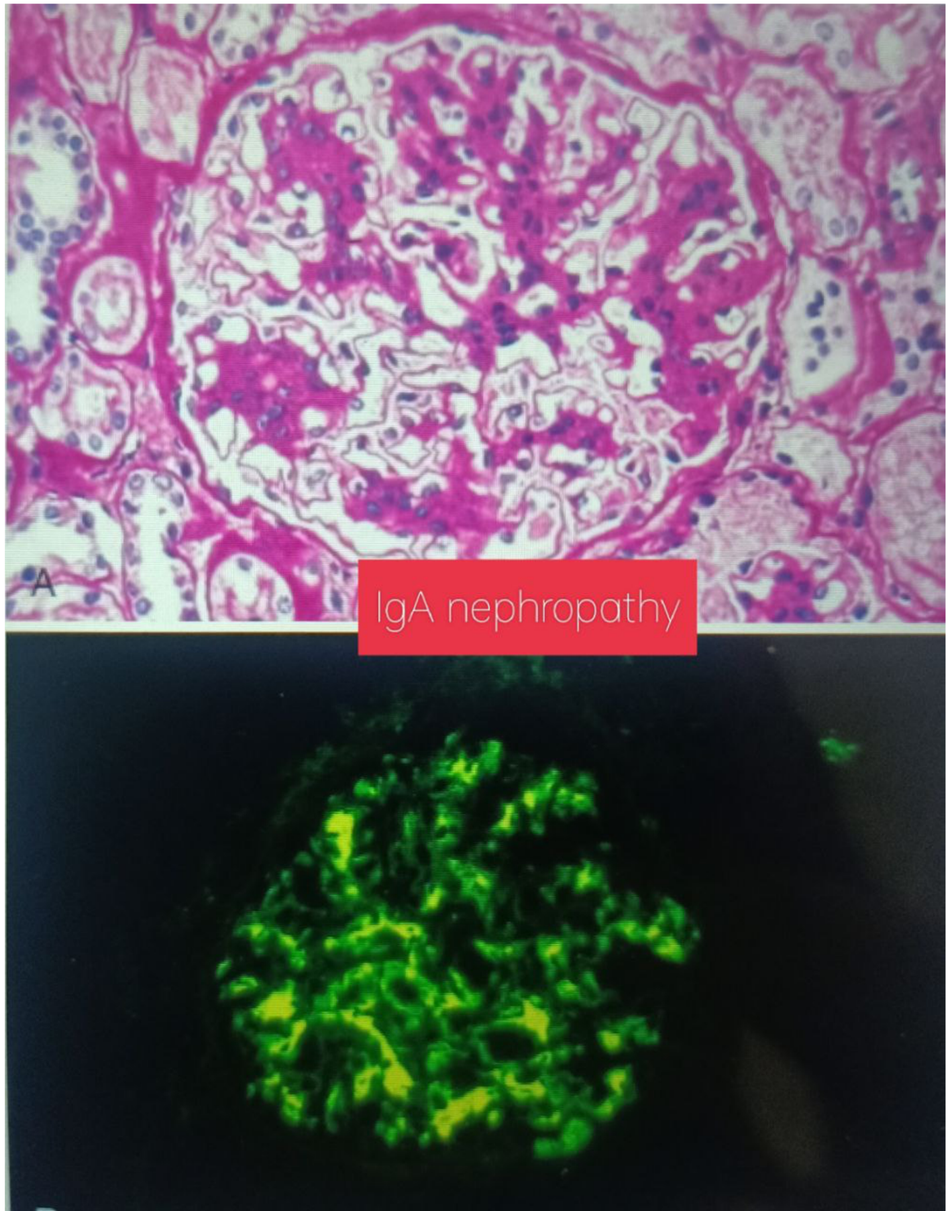

NEPHROTIC SYNDROME

Causes	Approximate Prevalence (%)[a]	
	Children	Adults
Primary Glomerular Disease		
Membranous nephropathy	3	30
Minimal change disease	75	8
Focal segmental glomerulosclerosis	10	35
Membranoproliferative glomerulonephritis and dense deposit disease[b]	10	10
Other proliferative glomerulonephritides (focal, "pure mesangial," IgA nephropathy)[b]	2	17
Systemic Diseases		
Diabetes mellitus		
Amyloidosis		
Systemic lupus erythematosus		
Drugs (nonsteroidal antiinflammatory, penicillamine, heroin)		
Infections (malaria, syphilis, hepatitis B and C, HIV)		
Malignant disease (carcinoma, lymphoma)		
Miscellaneous (bee-sting allergy, hereditary nephritis)		

TYPES OF NEPHROTIC SYNDROME

MINIMAL CHANGE DISEASE DISEASE,,MEMBRANOUS NEPHROPATHY ,,FSGS,,MPGN TYPE I.

MINIMAL CHANGE DISEASE

ALSO KNOWN AS LIPOID NEPHROSIS,,NIL DEPOSIT DISEASE.

MOST COMMON CAUSE OF NEPHROTIC SYNDROME IN CHILDREN.

UNDER LIGHT MICROSCOPE GLOMERULUS IS NORMAL APPEARING BUT UNDER ELECTRON MICROSCOPE THERE IS EITHER FUSIÓN OR EFFACEMENT OF PODOCYTE FOOT PROCESS.THIS CONDITION WHERE GLOMERULI IS NORMAL APPEARING WITH CLINICAL PRESENTATION OF NEPHROTIC SYNDROME,,,CAN BE IDIOPATHIC OR MAY HAVE SOME CAUSE KNOWN AS SECONDARY MINIMAL CHANGE DISEASE.

normal glomerulus

SECONDARY MINIMAL CHANGE DISEASE CAUSES

TABLE 18.1 Secondary Causes of Minimal Change Disease

Causes	Examples
Drugs	NSAIDs, interferon-α, lithium (rare: usually causes chronic interstitial nephritis), tamoxifen, antimicrobials (ampicillin, rifampicin, cefixime), gold (rare: usually causes membranous nephropathy), mercury in skin-lightening products
Allergy	Pollen, house dust, insect stings, poison oak
Hematologic conditions	Hodgkin disease, non-Hodgkin lymphoma, leukemia, hemophagocytic syndrome, myelodysplastic syndrome
Solid organ tumors	Most commonly lung, colorectal, renal cell carcinoma, thymoma (rare: pancreatic, breast, bladder, ovarian)
Other	Immunizations

NSAIDs, Nonsteroidal antiinflammatory drugs.

SOME FACTUAL POINTS ON PATHOGENESIS OF MCD

1]CIRCULATORY FACTORS CAUSING NEPHROTIC SYNDROME:-CYTOKINES,,HEMOPEXIN,,MICROBIAL PRODUCTS

2] LOSS OF ANIONIC CHARGE OF GBM DUE TO LOSS OF HEPARAN SULPHATE.

3] ELECTROKINETIC MODEL

4]PODOCYTE DYSFUNCTION [CD80,,C MIP,,ANGPTI4

5] role of b cell:-anti cd 20 mab shows remission in some pt of MCD.

clinical features:-rapid onset pitting edema in both lower limbs. Can be found in genitals,bilateral peri orbital edema that can be confused with allergic process.THERE CAN BE ANASARCA,,PLEURAL EFFUSION.BOWEL EDEMA MAY PRESENT AS DIARRHEA.ABDOMINAL PAIN AND NAUSEA ALSO OCCUR.PAIN IS DUE TO ASCITES AND IS RELIEVED AFTER ALBUMIN INFUSION.URINE CAN BE FROATHY AND NAILS MAY HACE WHITE LINES KNOWN AS MUEHRCKE LINES.MACROSCOPIC HEMATURIA INDICATED RENAL VEIN THROMBOSIS

Q:-Pt OF MCD IS ALWAYS HYPOTENSIVE:-T/F

F:-CAN BE NORMOTENSIVE. IN FACT 20% Pt OF MCD ARE HYPERTENSIVE ON ONSET,,WHICH IS RENIN MEDIATED AND TRANSIENT.

HYPERLIPIDEMIA IN Pt OF MCD.

HIGH TOTAL CHOLESTEROL AND LDL. IF PROTEINURIA IS SEVERE THEN TG AND VLDL ARE ALSO HIGH.

CAUSES OF HYPERLIPIDEMIA:-INCREASED HEPATIC SYNTHESIS,,ALTERED EXPRESSION OF PCSK9,,LOW LIPOPROTEIN LIPASE ACTIVITY.

25% PATIENTS OF MCD DEVELOPE ACUTE KIDNEY INJURY DUE TO EXCESSIVE DIURETIC THERAPY CAUSING INTRAVASCULAR VOLUME DEPLETION OR LOCAL RELEASE OF ENDOTHELIN 1 IN RENAL VASCULAR BED CAUSING LOCAL VASOCONTRICTION.DUE TO HYPOALBUMINEMIA TOTAL CALCIUM IS LOW AS CALCIUM BINDS TO ALBUMIN,, BUT IONIC CALCIUM IS NORMAL.

INFECTIONS IN MCD:- DUE TO DISRUPTION OF ALTERNATE PATHWAY OF COMPLEMENT DUE TO URINARY LOSS OF FACTOR B AND I.[JUST REMEMBER THIS].LOSS OF IMMUNOGLOBULINS IN URINE.

PNEUMONIA,,PERITONITIS,,UTI.CAUSED BY STREPTOCOCCI PNEUMONAE,,HAEMOPHILUS AND E.COLI.

THROMBOSIS IN MCD:-ANTITHROMBIN III,,PRITEIN C,,,PROTEIN S;HIGH FACTOR V,VII,VIII,X,XII WITH HYPOVOLEMIA AND RSULTING THROMBOCYTOSIS.

MEMBRANOUS NEPHROPATHY

THE NAME GIVEN IS DUE TO THE APPEARANCE OF GLOMERULI ON LIGHT MICROSCOPE,,THAT SHOWS THICKENING OF WALLS OF GLOMERULI,,BUT WITHOUT PROLIFERATION. IMAGE OF GLOMERULI SHOWN AFTERWARDS.

MEMBRANOUS NEPHROPATHY CAN BE IDIOPATHIC (PRIMARY) OR DUE TO SOME OTHER UNDERLYING DISEASE (SECONDARY MEMBRANOUS NEPHROPATHY).

PRIMARY MEMBRANOUS NEPHROPATHY HAS ANTIBODY AGAINST PLA2R(MOSTLY),,AND SOMETIMES AGAINST NELL1,,THSD7A,,Sema3B,,PCDH7,,HTRA1.

SECONDARY MEMBRANOUS NEPHROPATHY CAUSES

AUTOIMMUNE DISEASES LIKE LUPUS NEPHRITIS CLASS V,, OR SOME UNCOMMON DISEASES LIKE RA,,AUTOIMMUNE THYROID DISEASE,,IgG4 RELATED DISEASE,,CRESCENTIC GLOMERULONEPHRITIS.

INFECTIONS LIKE HBV,, OR SOME UNCOMMON ONES LIKE HIV,,HCV,,SYPHILLIS,SCHISTOSOMIASIS.

MALIGNANCY LIKE PROSTATE,BREAST,,LUNG ,,COLON,,STOMACH,,KIDNEY,, OR SOME UNCOMMON LIKE NON HODGKINS ,,MELANOMA,,CLL.

DRUGS LIKE NSAIDS AND COX2 INHIBITORS.

MISCELANNEOUS LIKE SARCOIDOSIS.

CLINICAL FEATURES

70-80% HAVE NEPHROTIC SYNDROME .10-20% HAVE HTN.

MICROSCOPIC HEMATURIA IN 30-40% CASES WITHOUT RED CELL CAST.

THERE MAY BE SEEN FATTY CAST IN URINE SEDIMENT . SEE IMAGE AHEAD

MEDICAL LABORATORY SCIENTIST
MLS
www.MedicalLabScientist.org

OTHER PATIENTS MAY PRESENT WITH ASSYMPTOMATIC SUBNEPHROTIC NON SELECTIVE PROTEINURIA,,THE DIAGNOSIS OF WHICH MAY BE MADE MONTHS OR YEARS AFTER.

DIAGNOSIS

LIGHT MICROSCOPY:-THICKENED WALL OF CAPILLARY OF GLOMERULI.

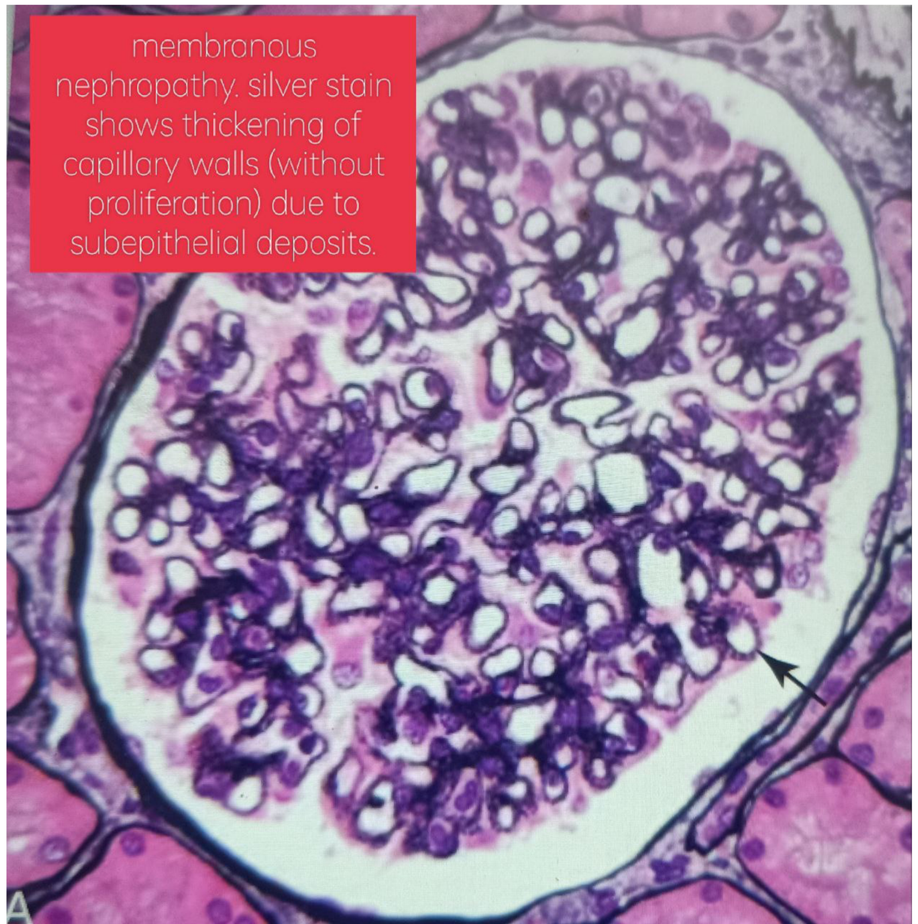

IMMUNOFLUORESCENCE [GRANULAR PATTERN]

PRIMARY MEMBRANOUS NEPHROPATHY

IgA,,IgM ABSENT; IgG4 PREDOMINENCE.
MESANGIAL Ig ABSENT;C1q NEGATIVE/WEAK
PLA2R POSITIVE AND STAINS AT THE SAME SITE AS IgG.

IgA AND/OR IgM MAY BE PRESENT
IgG 1/2/3 PREDOMINENT
MESANGIAL Ig STAINING MAY BE PRESENT.
C1q POSITIVE
PLA2R NEGATIVE.

ELECTRON MICROSCOPE
SUBEPITHELIAL DEPOSITS.

SEE IMAGES IN NEXT SLIDE

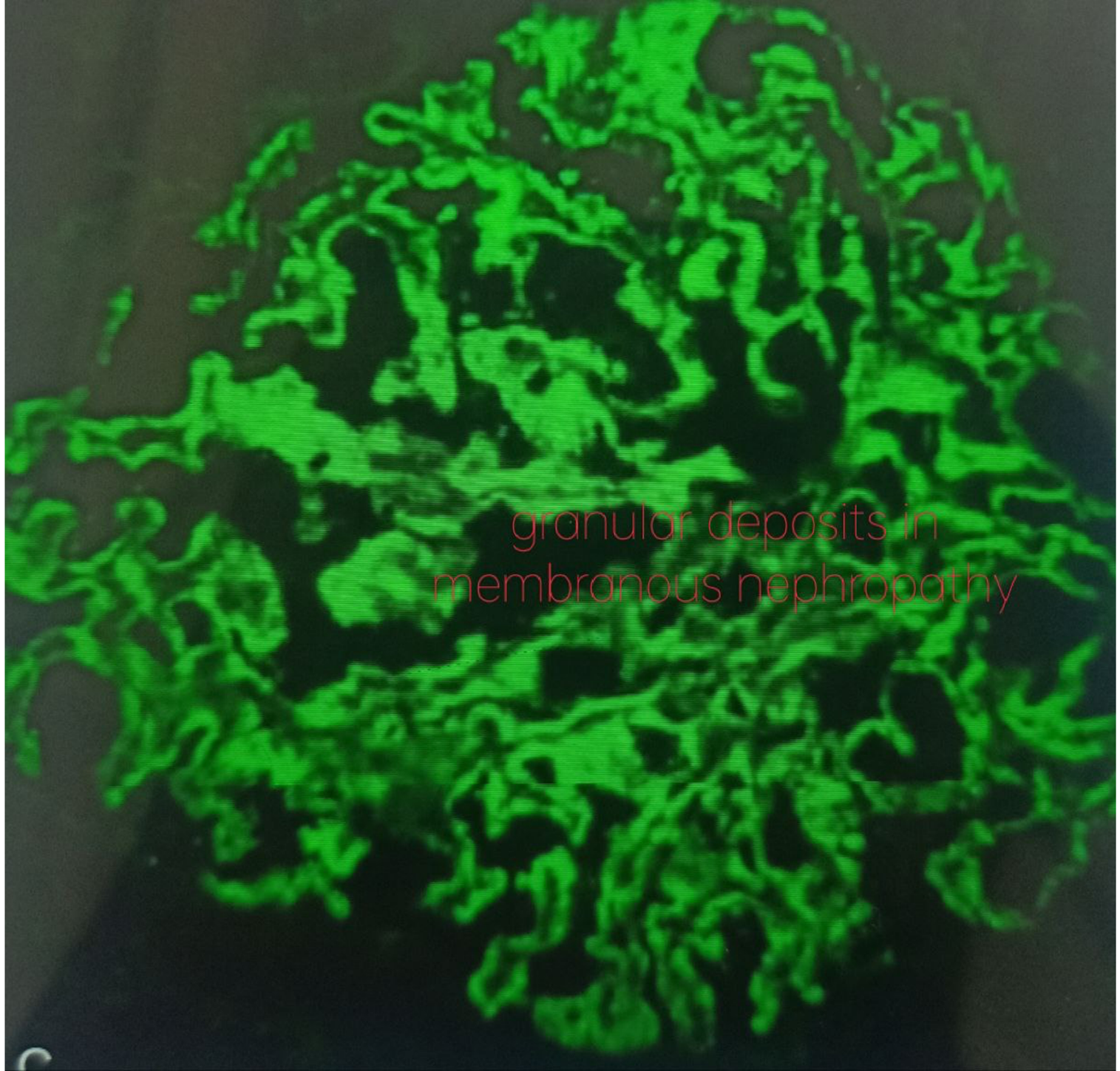
granular deposits in
membranous nephropathy

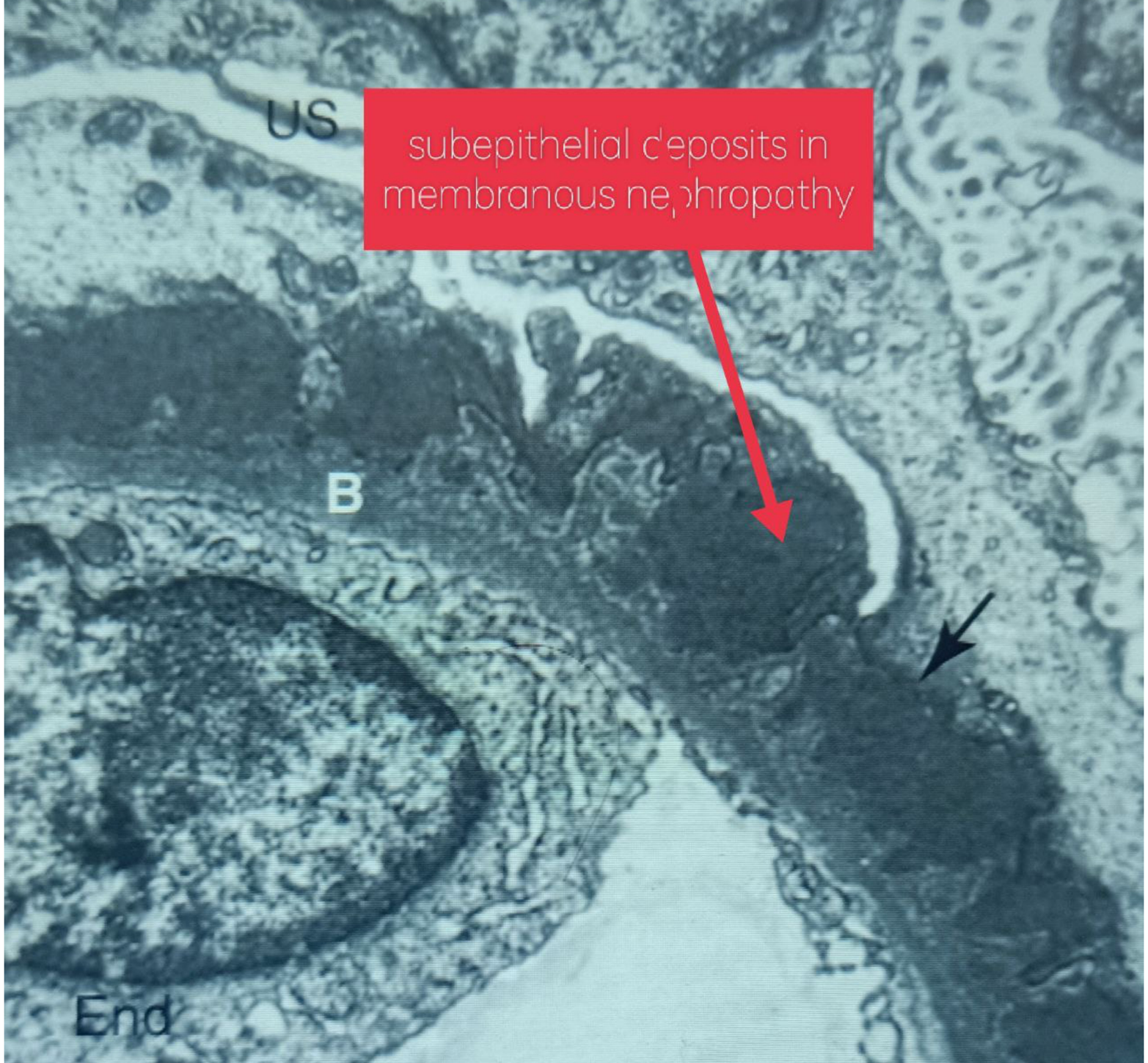
US
subepithelial deposits in
membranous nephropathy
B
End

MEMBRANOPROLIFERATIVE GLOMERULONEPHRITIS[MPGN]

CLASSIFICATION OF MPGN BASED ON ELECTRON MICROSCOPY FINDINGS [OLD CLASSIFICATION]

1] TYPE I MPGN:- MESANGIAL AND SUBENDOTHELIAL DEPOSITS

2]TYPE 2 MPGN:-MESANGIAL AND INTRAMEMBRANOUS[GLOMERULUR BASEMENT MEMBRANE] ELECTRON DENSE[SOMETHING THAT IS DARK UNDER EM]

3]TYPE 3 MPGN:-

SUBENDOTHELIAL,SUBEPITHELIAL,INTRAMEMBRANOUS DEPOSITS.

NEWER CLASSIFICATION.

TYPE 1:-DEPOSITION OF MONOCLONAL IMMUNOGLOBULINS OR IMMUNE COMPLEX WITH OR WITHOUT COMPLEMENT DEPOSITION UNDER IMMUNOFLUORESCENCE MICROSCOPE.

TYPE 2:-COMPLEMENT DEPOSITION.

TYPE3:-NO IMMUNE COMPLEX NO IMMUNOGLOBULINS DEPOSITION.

DUE TO INFLAMMATION OF GLOMERULI IN MPGN,, THERE OCCURSE REPAIRRATIVE PHASE,, IN WHICH THE DAMAGED ENDOTHELIUM AND MESANGIAL CELLS MAKE NEW BASEMENT MEMBRANE. UNDER EM GBM NOW APPEARS THICK TAM TRACK DOUBLE CONTOURED.[IMAGE SHOWN AHEAD],,AND APPEARS LOBULATED UNDER LM.[IMAGE AHEAD]

MPGN showing lobulated appearance.

CAUSES OF MPGN

1]IMMUNE COMPLEX DEPOSITION ASSOCIATED WITH INFECTION:-HBV HCV HIV MALARIA SCHISTOSOMIASIS LEISHMANIASIS MYCOPLASMA LEPROSY ENDOCARDITIS.

2] IMMUNE COMPLEX ASSOCIATED WITH AUTOIMMUNITY :-SLE SJOGREN RA

3]DEPOSITION OF MONOCLONAL IMMUNOGLOBULIN:-PLASMA CELL DYSCRASIA[MULTIPLE MYELOMA]

4]NON IMMUNOGLOBULIN NON NON COMPLEMENT.:-HEALING PHASE OF HUS/TTP,,APLA,,SICKLE CELL,,POLYCYTHEMIA,,POEMS SYNDROME

5] IDIOPATHIC

6]TUMOR:-CLL/NHL;7]ALPHA1 ATD

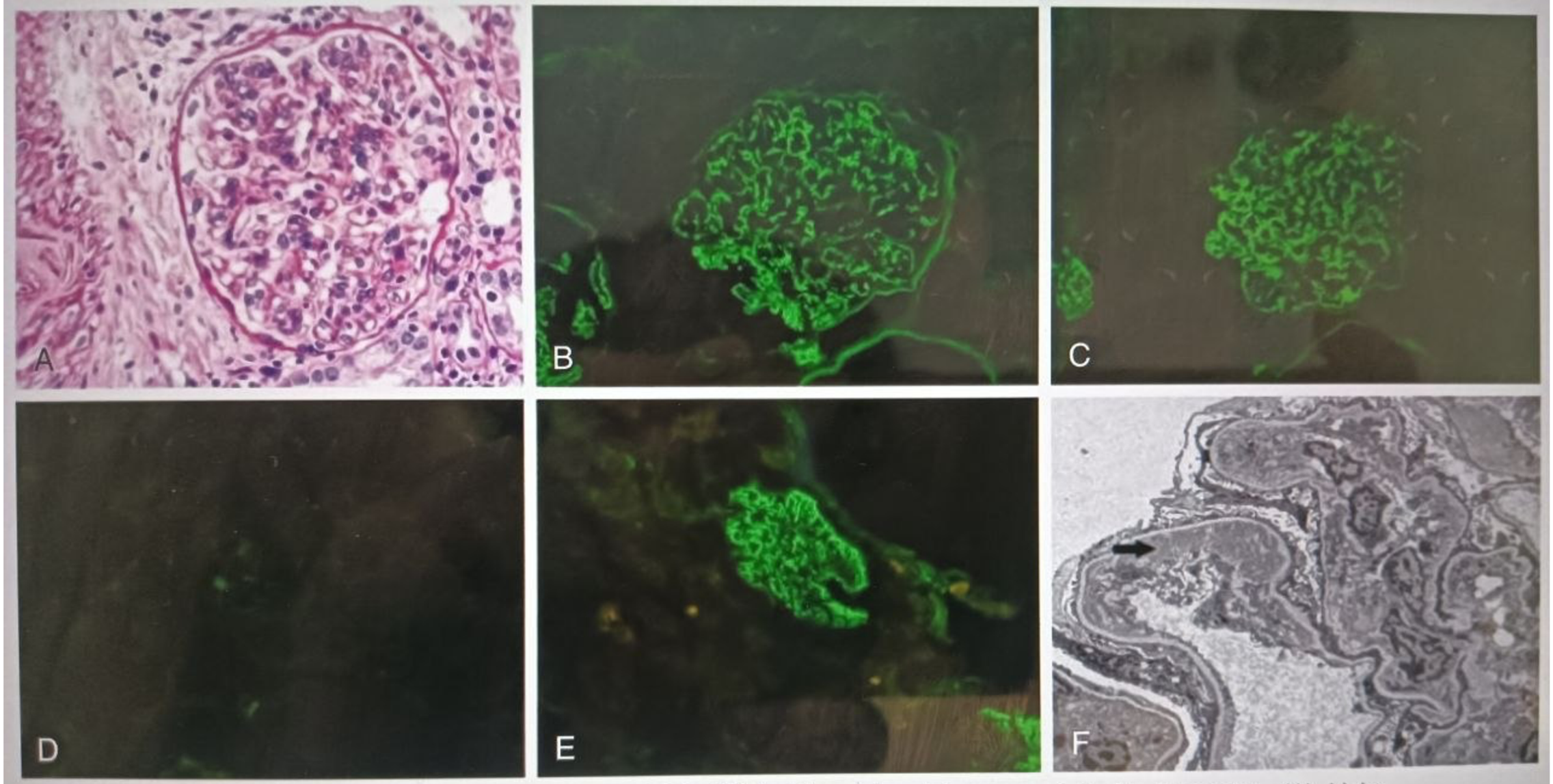

Fig. 22.2 Proliferative Glomerulonephritis With Monoclonal Immunoglobulin Deposits. (A) Light microscopy showing a membranoproliferative glomerulonephritis (MPGN) pattern of injury (PAS, ×40). (B–E) Immunofluorescence microscopy showing bright granular staining for immunoglobulin G (IgG) (B), kappa light chains (C), negative staining for lambda light chains (D), and positive staining for IgG3 subtype (E). (F) Electron microscopy showing subendothelial electron-dense deposits and double contour formation. *Black arrows* point to subendothelial deposits (F, ×4000.)

FOCAL SEGMENTAL GLOMERULOSCLEROSIS

I WOULD LIKE TO SAY THAT I WILL FIRST PROVIDE SOME BASIC PATHOGENESIS FACTS ABOUT FSGS THEN WE WILL PROCEED FURTHUR.WITHOUT UNDERSTANDING THESE FACTS[OR LOGIC IF U UNDERSTAND IT] U WILL FIND PROBLEM IN UNDERSTANDING PATHOPHYSIOLOGY OF CKD WHENEVER U STUDY CKD.

FACTORS THAT PREVENT LEAKAGE OF MACROMOLECULES[ALBUMIN,GLOBULINS ETC] VIA GLOMERULUS INTO BOWMAN SPACE.

1]THE FIRST FACTOR TO COME INTO ACTION IS THE GLYCOCALYX LAYER THAT LINES THE LUMINAL ASPECT OF THE ENDOTHELIAL LAYER OF GLOMERULUR CAPILLARIES . THIS GLYCOCALYX LAYER IS NEGATIVELY CHARGED SO IT REPELS ALBUMIN.

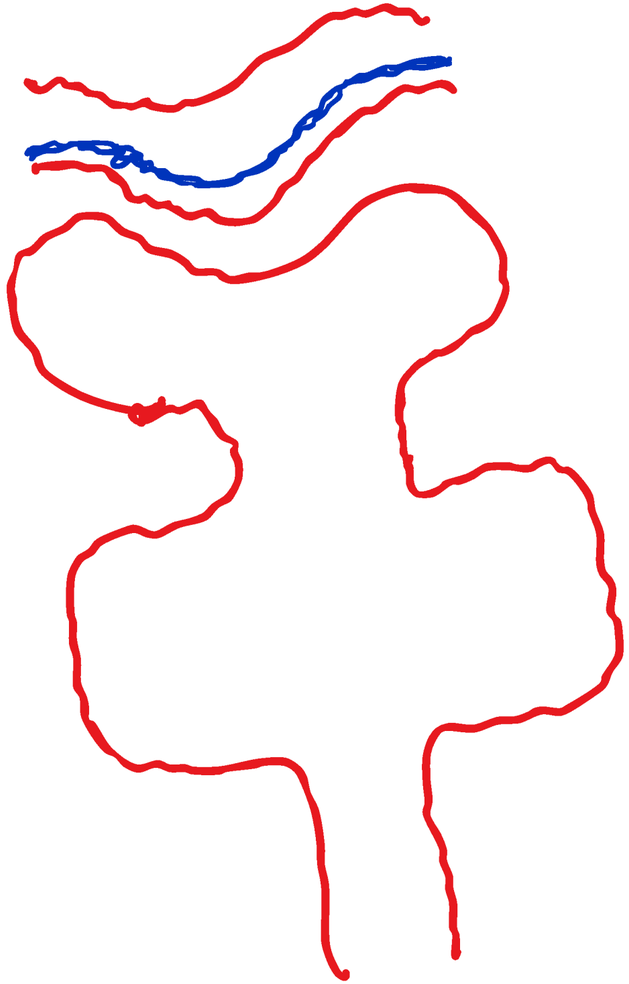

BLUE LAYER IS THE GLYCOCALYX LAYER LINING THE LUMINAL ASPECT OF GLOMERULUR ENDOTHELIAL CELLS

WHEN THERE IS INCREASE IN INTRAGLOMERULUR PRESSURE[GLOMERULUR HYDROSTATIC PRESSURES],, THIS GLYCOCALYX LAYER UNDERGOES THICKENING ,,,SIMILARLY WHEN BLOOD FLOW TO GLOMERULUS DECREASES,, THE GLYCOCALYX LAYER THICKNESS DECREASES.

2]THE FENESTRATED ENDOTHELIAL CELLS OF GLOMERULUR CAPILLARY.WHEN THERE IS GLOMERULUR HYPERTENSION THERE OCCURS STRETCHING OF GLOMERULUR WALLS WHICH INCREASES SIZE OF THESE PORES WHICH INCREASES THE PERMEABILITY TO ALBUMIN.

3] THE PODOCYTE FOOT PROCESS AND THE DIAPHRAGM. DAMAGE TO PODOCYTE CAUSES INCREASED PERMEABILITY TO ALBUMIN.NOW I WANT U TO FOCUS WITH PATIENCE TO WHAT IS NEXT AHEAD.

WHATEVER I WILL EXPLAIN NOW,, I HAVE ALSO DRAWN DIAGRAMS AT MY BEST SO THAT U CAN VISUALIZE WHAT IS HAPPENING.

WE WILL START FROM TWO PROCESSES :-

1]GLOMERULUR HYPERTENSION AND HYPERFILTRATION.

2]EFFECT OF PROTEINURIA ON PODOCYTES .

GLOMERULUR HYPERTENSION AND HYPERFILTRATION CAUSES MECHANICAL STRESS/SHEAR STRESS ON PODOCYTES,,, THIS INCREASES LOCAL PRODUCTION OF AT-II AS WELL AS AT-II RECEPTORS ON PODOCYTES . BINDING OF AT-II WITH ITS RECEPTOR ON PODOCYTE CAUSES DECREASED EXPRESSION OF NEPHRIN[DIAPHRAGM MEMBER].THIS EXPOSES PODOCYTE TO PROTEINS. PODOCYTES TAKE UP THESE PROTEINS [VIA A LIGAND FOR ALBUMIN KNOWN AS MEGALIN] AND THERE OCCURS PRODUCTION OF TGF BETA BY PODOCYTES WHICH CAUSES TWO THINGS.

FIRST,,APOPTOSIS OF THE PODOCYTE. DUE TO APOPTOSIS OF THE PODOCYTE,, THE REMAINING OF THE INTACT PODOCYTES WILL NOW HAVE TO HANDLE A GREATER AMOUNT OF SHEAR STRESS/GLOMERULUR PRESSURE.THIS WILL AGAIN INDUCE THE SAME CHANGES AND CONSEQUENCES THAT WE JUST UNDERSTOOD,, IN THE NEAR BY PODOCYTES. SO IN THIS WAY THERE WILL BE PROGRESSIVE DAMAGE TO ALL THE PODOCYTES OF THE GLOMERULUS.

TGF BETA ALSO CAUSES ACTIVATION OF MESANGIAL CELLS THAT DEPOSIT EXTRACELLULAR METRIX,, THIS CAUSES SCLEROSIS/FIBROSIS INSIDE THE GLOMERULUS CAUSING DECREASED BLOOD FLOW TO THE GLOMERULUS. DUE TO THIS ,, THE BLOOD IS DIVERTED TO THE REMAINING ADJACENT GLOMERULUS,, DUE TO THIS THE ADJACENT GLOMERULI WILL NOW SUFFER FROM INTRAGLOMERULUR HYPERTENSION,,THE EFFECT OF WHICH{GLOMERULOSCLEROSIS] I JUST EXPLAINED IN THE PREVIOUS SLIDES. THE CYCLE REPEATS.

THIS IS HOW THERE OCCURSE PROGRESSIVE RENAL DAMAGE. THIS ALSO EXPLAINS THE ROLE OF ACE INHIBITORS IN PREVENTING PROTEINURIA.NOW LET ME SHOW U A DIAGRAM SO THAT U CAN UNDERSTAND THE PREVIOUS SLIDES,, WHAT ACTUALLY HAPPENED.


AT-II
1
2
3
4
BOWMAN

The blue coloured cells with the receptor of AT-II ARE PODOCYTES. THE JUMPING ARROW FROM ONE PODOCYTE TO ANOTHER REPRESANTS THAT IF ONE PODOCYTE IS DAMAGED THEN THE OTHER IS ALSO DAMAGED,, CAUSING PROGRESSIVE PODOCYTE INJURY. THE STRAIGHT ARROWS WITHIN THE CAPILLARY LUMEN REPRESANT THE SHEAR STRESS ON PODOCY

Interstitial inflammation and fibrosis

we will now discuss two factors that cause release of pro inflammatory cytokines by PCT cells.

1] GLOMERULUR injury causing proteinuria
2] chronic ischaemia/hypoxia causing release of pro inflammatory cytokines by PCT cells.

1]glomerulur injury:- GLOMERULUR INJURY CAUSES PROTEINURIA,, EXCESS ALBUMIN IS TAKEN UP BY PCT CELLS ,,THIS CAUSES RELEASE OF INFLAMMATORY CYTOKINES BY PCT CELLS WITHIN THE INTERSTITIUM,,OVER TIME THIS CAUSES FIBROSIS AS A HEALING RESPONSE TO INFLAMMATORY INSULT.

CHRONIC ISCHAEMIA/VASCULAR INJURY

CHRONIC ISCHAEMIA INCREASES AT-II IN REGION OF HYPOXIA,,THIS CAUSES CONSTRICTION OF EFFERENT ARTERIOLE ,,,THIS DECREASES BLOOD FLOW IN PERITUBULAR CAPPILARIES. THIS DECREASES OXYGEN SUPPLY TO CELLS OF PCT,,THIS CAUSES RELEASE OF INFLAMMATORY CYTOKINES BY PCT CELLS INTO THE INTERSTITIUM,,WHICH CAUSES FIBROSIS AS A HEALING RESPONSE .

THIS FIBROSIS INCREASES THE DISTANCE BETWEEN PCT CELLS AND PERITUBULAR CAPILLARY ,,, SO AGAIN THERE IS HYPOXIA ,,, MOREOVER ,, DUE TO DEATH OF PCT CELLS OF ONE NEPHRON,, THE OTHER NEPHRONS ADJACENT TO IT WILL SUFFER INCREASED FUCTIONAL LOAD ,, THIS WILL ALSO GENERATE A GREATER HYOXIC ENVIROMENT ,, WHICH WILL IN TURN CAUSE MORE FIBROSIS. AS FIBROSIS INCREASES THERE OCCURS PROGRESSIVE RENAL DAMAGE. HOPE U GET IT.

DONT MEMORISE THIS TABLE,,JUST USE THIS TO SOLVE QUESTIONS

BOX 19.1 Etiologic Classification of Focal Segmental Glomerulosclerosis

Primary
- Presumably mediated by circulating/permeability factor(s)

Genetic Causes
- (See Chapter 20)

Secondary

Virus Associated
- HIV-1 (HIV-associated nephropathy)
- SARS-CoV-2 (COVID-19 associated nephropathy)
- Parvovirus B19
- CMV
- EBV

Drug Induced
- Interferon
- Pamidronate
- Sirolimus
- Anabolic steroids

Adaptive Changes to Glomerular Hyperfiltration

Reduced Kidney Mass
- Oligomeganephronia
- Very low birth weight (correlating with low nephron endowment)
- Unilateral kidney agenesis
- Kidney dysplasia
- Reflux nephropathy
- Sequela to cortical necrosis
- Surgical kidney ablation
- Any advanced kidney disease with reduction in functioning nephrons

Initially Normal Kidney Mass
- Hypertension
- Atheroemboli or other acute vasoocclusive processes
- Obesity
- Bodybuilders
- Cyanotic congenital heart disease
- Sickle cell anemia

Uncertain Cause

PATHOLOGY OF FSGS

TYPES:COLLAPSING,, TIP,,CELLULAR,,PERIHILAR,,NOS

I HAVE JUST PROVIDED THE TABLE WHICH UNDERLINES DIFFERENT ENTITIES ASSOCIATED WITH DIFFERENT TYPES OF PATHOLOGICAL TYPE.I HAVE NOT PROVIDED HISTOLOGY OF ALL DIFFERENT TYPES.

FSGS PATHOLOGY

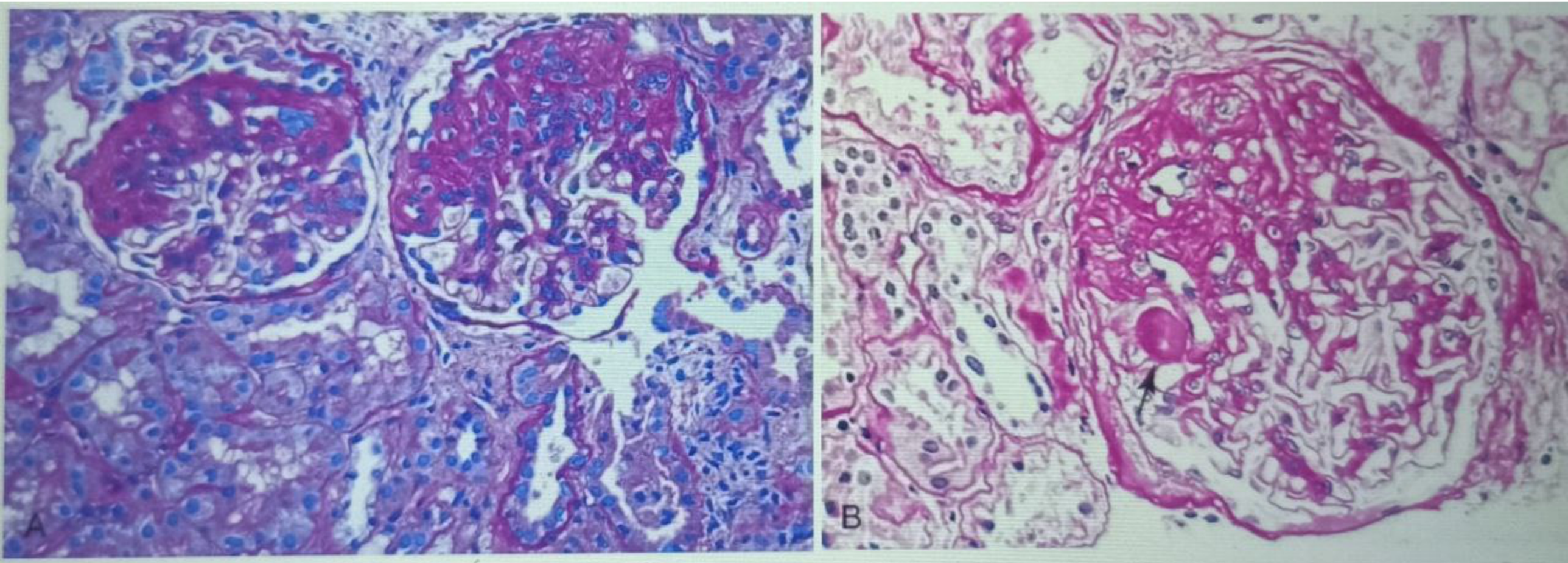

gure 20.14 Focal segmental glomerulosclerosis, periodic acid–Schiff stain. (A) Segmental sclerosis involves the upper half of both glomeruli. High-power view showing hyaline insudation *(arrow)* and lipid (small vacuoles) in sclerotic area.

TABLE 19.1 Morphologic Variants of Focal Segmental Glomerulosclerosis : Columbia Classification

Variant	Defining Features	Clinical Features	Associations
Collapsing	Implosive retraction of capillaries with overlying GEC hyperplasia, severe tubular injury, tubular microcysts, severe FPE	Primary or secondary, severe nephrotic syndrome and AKI, Black racial predominance, worst prognosis	Viral infections (HIV, SARS-CoV-2, CMV), autoimmune SLE, drugs (pamidronate, INF), vasoocclusion, *APOL1*
Tip	Adhesion of tuft at tubular pole with foam cells, severe FPE	Usually primary, abrupt-onset nephrotic syndrome	Usually steroid responsive, favorable prognosis
Cellular	Expansile lesion with endocapillary hypercellularity (foam cells, leukocytes)	Usually primary	
Perihilar	Hyalinosis and sclerosis centered at vascular pole, glomerulomegaly, focal FPE	Usually secondary, adaptation to glomerular hyperfiltration	Obesity, HTN, low nephron number, sickle cell nephropathy
NOS	Does not meet criteria for any above variant	Most common variant, primary or secondary	

FPE, foot process effacement; FSGS, focal segmental glomerulosclerosis; GEC, glomerular epithe-

CLINICAL FEATURES

PRIMARY FSGS PRESENTS WITH NEPHROTIC RANGE PROTEINURIA WHILE SECONADRY TYPE MAY HAVE SUBCLINICAL PROTEINURIA. PROTEINURIA IN FSGS IS NONSPECIFIC[PROTEINS OTHER THEN ALBUMIN ARE ALSO PRESENT]. 30-65% PATIENT OF FSGS ARE HTNsive AT PRESENTATION.30-75% HAVE MICROHEMATURIA. SOMETIMES GLYCOSURIA,,PHOSPHATURIA AND AMINOACIDURIA MAY BE PRESENT INDICATING TUBULAR DAMAGE.

ACUTE TUBULAR INJURY

ATI IS THE MOST COMMON CAUSE OF AKI.

S3/STRAIGHT PART OF GLOMERULI IS AFFECTED IN ATI.

PATHOGENESIS OF ATI

RENAL ISCHAEMIA CAUSES PCT DAMAGE ,,AS PCT ABSORBS SODIUM,, DUE TO DAMAGE SODIUM WILL NOT BE ABSORBED,, SO EXCESS SODIUM IS DELIEVERED TO DCT[TO BE SPECIFIC,,MACULA DENSA],,MACULA DENSA SENSES THIS INCREASED AMOUNT OF SODIUM,, AND INTERPRETS THIS AS INCREASE IN GFR,, SO IT CAUSES CONSTRICTION OF AFFERENT ARTERIOLE,, THIS DECREASES GFR FURTHUR,, THIS IS CALLED

TUBULOGLOMERULUR RÉFLEX. THIS CAUSES OLIGURIA,,AZOTEMIA,,HYPERKALEMIA,,METABOLIC ACIDOSIS.

IN RECOVERY PHASE OF ATI WHEN GFR IS COMING TO NORMAL,, BUT THE PCT IS STILL DAMAGED ,,HENCE THE FILTERED POTASSIUM AND FLUID WILL NOT BE ABSROBED CAUSING HYPOKALEMIA[MAY CAUSE MUSCLE WEAKNESS] AND POLYURIA.

CAUSES OF ATI

Ischemic causes :-Shock:-cardiogenic shock, septic shock, anaphylactic shock, hypovolaemic shock, [vomiting, diarrhoea, haemorrhage]
:-Thromboembolic event:-Cholesterol embolisation from ascending iota or abdominal aorta into the renal artery,, cardiac vegetation as in RF, SLE, antiphospholipid antibody syndrome and infective endocarditis

:-Mural thrombi:-post myocardial infarction and atrial fibrillation,, aneurysm of Aorta.

:-HUS-TTP[shigella, e.coli, HIV,, scleroderma,, SLE,, inherited.]

:-Vasculitis[polyarteritis nodosa]

Toxins and drugs :-haemoglobinuria,, myoglobinuria,, bile nephropathy.

Pyonephritis
Light chain nephropathy [plasma cell dyscrasia] Minimum

Infection : leptospirosis.

PATHOPHYSIOLOGY OF RENAL ARTERY STENOSIS

1] 70 to 80% obstruction in the renal artery must occur before hypertension to occur. The increase in blood pressure in case of renal artery stenosis is actually a compensatory mechanism to restore the renal perfusion.

BILATERAL RENAL ARTERY STENOSIS

In bilateral renal artery stenosis,, there is obstruction in both the renal arteries, this causes stimulation of RAAS. As both the renal arteries are stenosed,, none of the kidneys will be able to excrete sodium and water. This will cause hypervolaemia which will inhibit the RAAS. Since RAAS is inhibited,, the drugs that work on RAAS,, will not be effective.

UNILATERAL RENAL ARTERY STENOSIS

In this case, only one of the renal artery is stenosed,, the second kidney will be hyper perfused
This will cause pressure natriuresis. Since the renal is stenosed,, there will be RAAS activation. In this case, there will be no inhibition of RAAS as there is pressure natriuresis,, hence unilateral stenosis will respond to drugs that inhibit RAAS.

Angiotensin-II causes Vasoconstriction, left ventricular hypertrophy, salt, and water retention, stimulates secretion of Aldosterone, endothelin release, sympathetic nervous system activation.

In renal artery, stenosis, the levels of angiotensin-II Will be high, so there will be efferent arteriolar constriction. This will increase the intra glomerular pressure. This will cause hyper filtration, maintaining the GFR, hence in a patient of renal artery stenosis, if drug that inhibit RAAS are given, then the levels of angiotensin will decrease. This will cause, Efferent arteriolar dilation,, this will decrease the intra glomerular pressure which will decrease the GFR. Hence, this will precipitate acute kidney injury. So whenever a patient of hypertension is given ACE inhibitors and if he comes to the clinic with high levels of creatinine and urea,[AKI],, this means there is underlying Reno vascular hypertension

Causes of bilateral and unilateral RAS

Table 48.1 Examples of Vascular Lesions Producing Renal Hypoperfusion and the Syndrome of Renovascular Hypertension

Unilateral Disease (Analogous to Two-Kidney–One-Clip Hypertension)
Unilateral atherosclerotic renal artery stenosis
Unilateral fibromuscular dysplasia[193]
Medial fibroplasia
Perimedial fibroplasia
Intimal fibroplasia
Medial hyperplasia
Renal artery aneurysm
Arterial embolus
Arteriovenous fistula (congenital/traumatic)
Segmental arterial occlusion (posttraumatic)
Extrinsic compression of renal artery (e.g., pheochromocytoma)
Renal compression (e.g., metastatic tumor)
Bilateral Disease or Solitary Functioning Kidney (Analogous to One-Kidney–One-Clip Model)
Stenosis to a solitary functioning kidney
Bilateral renal artery stenosis
Aortic coarctation
Systemic vasculitis (e.g., Takayasu's arteritis, polyarteritis)
Atheroembolic disease
Vascular occlusion due to endovascular aortic stent graft

Clinical features of RAS

SUDDEN OCCLUSION OF RENAL ARTERY CAN CAUSES MALIGNANT HTN

GRADUAL OBSTRUCTION AS IN ATHEROSCLEROSIS CAUSES WORSENING OF PREVIOUS HTN WITH A SLIGHT INCREASE IN CREATININE.

CAUSES OF AKI

PRERENAL,,INTRARENAL,,POSTRENAL.

PRERENAL CAUSES OF AKI:-ANYTHING THAT DECREASES INTRAVASCULAR/EFFECTIVE ARTERIAL BLOOD VOLUME WILL BE KNOWN AS PRERENAL AKI. NOTE THAT AKI STARTS WHEN MEAN ARTERIAL PRESSURE FALLS BELOW 65 mmHg.

CAUSES OF PRERENAL AKI ARE:-volume depletion like vomiting, diarrhoea, burns, haemorrhage that can be internal or external, sepsis, pancreas,rhabdomyolysis,ascitis, heart failure known as cardio, renal syndrome,diuretic overdose, Compartment syndrome, end, nephrotic syndrome, if the edema decreases the effective arterial blood volume causing renal hypoperfusion.

RENAL/INTRARENAL CAUSES OF AKI:-ATI, glomerulonephritis, tubulointerstitial nephritis,, vascular causes, like vasculitis, malignant hypertension,, HUS/TTP, cholesterol, embolisation, giving ACE inhibitors in case of bilateral RAS,sepsis due to toxins.

POSTRENAL CAUSES:- URINARY TRACT OBSTRUCTION.

IF PRERENAL AKI IS PROLONGED IT CAN DAMAGE TUBULES CAUSING ATI.

TABLE FOR DIFFERENCE BETWEEN PRERENAL AND INTRARENAL AKI.DONT MEMORISE THE TABLE,,JUST USE DURING SOLVING QUESTIONS.

Table 31.10 Urine Indices Used in the Differential Diagnosis of Prerenal Acute Kidney Injury and Acute Tubular Necrosis

Diagnostic Index	Prerenal Acute Kidney Injury	Acute Tubular Necrosis
Fractional excretion of sodium (%)	<1*	>2*
U_{Na} (mmol/L)	<20	>40
Urine creatinine/ plasma creatinine ratio	>40	<20
Urine urea nitrogen/ plasma urea nitrogen ratio	>8	<3
Urine specific gravity	>1.018	≈1.010
Urine osmolality (mOsm/kg H_2O)	>500	≈300
Plasma BUN/creatinine ratio	>20	<10-15
Renal failure index, $U_{Na}/(U_{Cr}/P_{Cr})$	<1	>1
Urine sediment	Hyaline casts	Muddy-brown granular casts

*Fractional excretion of sodium (FE_{Na}) may be >1% in prerenal acute kidney injury associated with diuretic use and/or in the setting of bicarbonaturia or chronic kidney disease; FE_{Na} often <1% in acute tubular necrosis caused by radiocontrast media or rhabdomyolysis.

BUN, Blood urea nitrogen; P_{Cr}, plasma creatinine concentration; U_{Cr}, urine creatinine concentration; U_{Na}, urinary sodium concentration.

OTHER CONDITIONS CAUSING HIGH CREATININE:- GLUCOCORTICOID USE,,HIGH PROTEIN BREAKDOWN,,GI BLEED,,HYPERALIMENTATION.

AKI STAGES

Table 31.4 RIFLE, Acute Kidney Injury Network, and Kidney Disease: Improving Global Outcomes Definitions and Staging of Acute Kidney Injury

Definitions

	RIFLE	AKIN	KDIGO
Serum creatinine level	An increase of >50% developing over <7 days	An increase of ≥0.3 mg/dL or of >50% developing over <48 hr	An increase of ≥0.3 mg/dL developing over <48 hr; or an increase of >50% developing over <7 days
Urine output*	<0.5 mL/kg/hr for >6 hr	<0.5 mL/kg/hr for >6 hr	<0.5 mL/kg/hr for >6 hr

Staging Criteria

RIFLE	Increase in Serum Creatinine Level	AKIN	Increase in Serum Creatinine Level	KDIGO	Increase in Serum Creatinine Level	Urine Output*
Risk	≥50%	Stage 1	≥0.3 mg/dL; or ≥50%	Stage 1	≥0.3 mg/dL; or ≥50%	<0.5 mL/kg/hr for >6 hr
Injury	≥100%	Stage 2	≥100%	Stage 2	≥100%	<0.5 mL/kg/hr for >12 hr
Failure	≥200%	Stage 3	≥200%	Stage 3	≥200%	<0.5 mL/kg/hr for >24 hr or anuria for >12 hr
Loss	Need for renal replacement therapy for >4 wk					
End-stage	Need for renal replacement therapy for >3 mo					

*The urine output criteria for both definition and staging of acute kidney injury are the same for the RIFLE, AKIN, and KDIGO criteria.
AKIN, Acute Kidney Injury Network; KDIGO, Kidney Disease: Improving Global Outcomes; RIFLE, Risk, Injury, Failure, Loss and End-stage kidney disease.

COMPLICATIONS OF AKI

Table 31.14 Common Complications of Acute Kidney Injury

Metabolic	Cardiovascular	Gastrointestinal	Neurologic	Hematologic	Infectious	Other
Hyperkalemia	Pulmonary edema	Nausea	Neuromuscular irritability	Anemia	Pneumonia	Hiccups
Metabolic acidosis	Arrhythmias	Vomiting	Asterixis	Bleeding	Septicemia	Elevated parathyroid hormone level
Hyponatremia	Pericarditis	Malnutrition	Seizures		Urinary tract infection	Low total triiodothyronine and thyroxine levels
Hypocalcemia	Pericardial effusion	Hemorrhage	Mental status changes			Normal thyroxine level
Hyperphosphatemia	Hypertension					
Pulmonary embolism	Myocardial infarction					
Hypermagnesemia						
Hyperuricemia						

QUESTIONS

THESE ARE NOT MY QUESTIONS,, THEY ARE FROM CERTAIN GOOD SOURCE.

EVERY ANSWER HAS ITS EXPLANATION EITHER IN MY NOTES SECTION OR ALONG WITH QUESTIONS,, SO U SHOULD KNOW WHERE TO FIND THE INFORMATION RELATED TO THE ANSWER IN THE NOTES SECTION.FOR THIS U HAVE TO BE THOROUGH THROUGH THE NOTES.

A 23 year old man goes out for his birthday and drinks, 10 pints of strong lager,, following which he has polyuria and passes large volumes of urine. His blood results are shown below.

Sodium normal
Potassium normal
Urea increased creatinine high

Which is the most important physiological adaptation to his intake of large volumes of lager?

A] increased renin level
B] reduced angiotensin level
C] reduce expression of renal aquaporin channels
D] increase GFR
E] increased ADH levels

ANSWER IN NEXT SLIDE

The meaning of the question is the boy drinks, large quantities of fluids, the intravascular blood volume will increase immediately,,in order to get the intravascular blood volume back to normal,, what are the physiological changes done by the body?

In this case, there is hypervolaemia, which will decrease renin levels, so option a wrong
It's a fact that a sudden increase in blood volume only minimally changes the GFR option D wrong
In this case, there is hypervolaemia, which will decrease ADH levels, so option E wrong
On solving MCQ day by day, what I learnt that in order to reach the answer, just go with the symptom given in the question to which you have the strongest grip. In this case, the symptom is polyuria. Now I will provide you a table from Harrison that shows approach to polyuria and I will explain how to reach the answer.

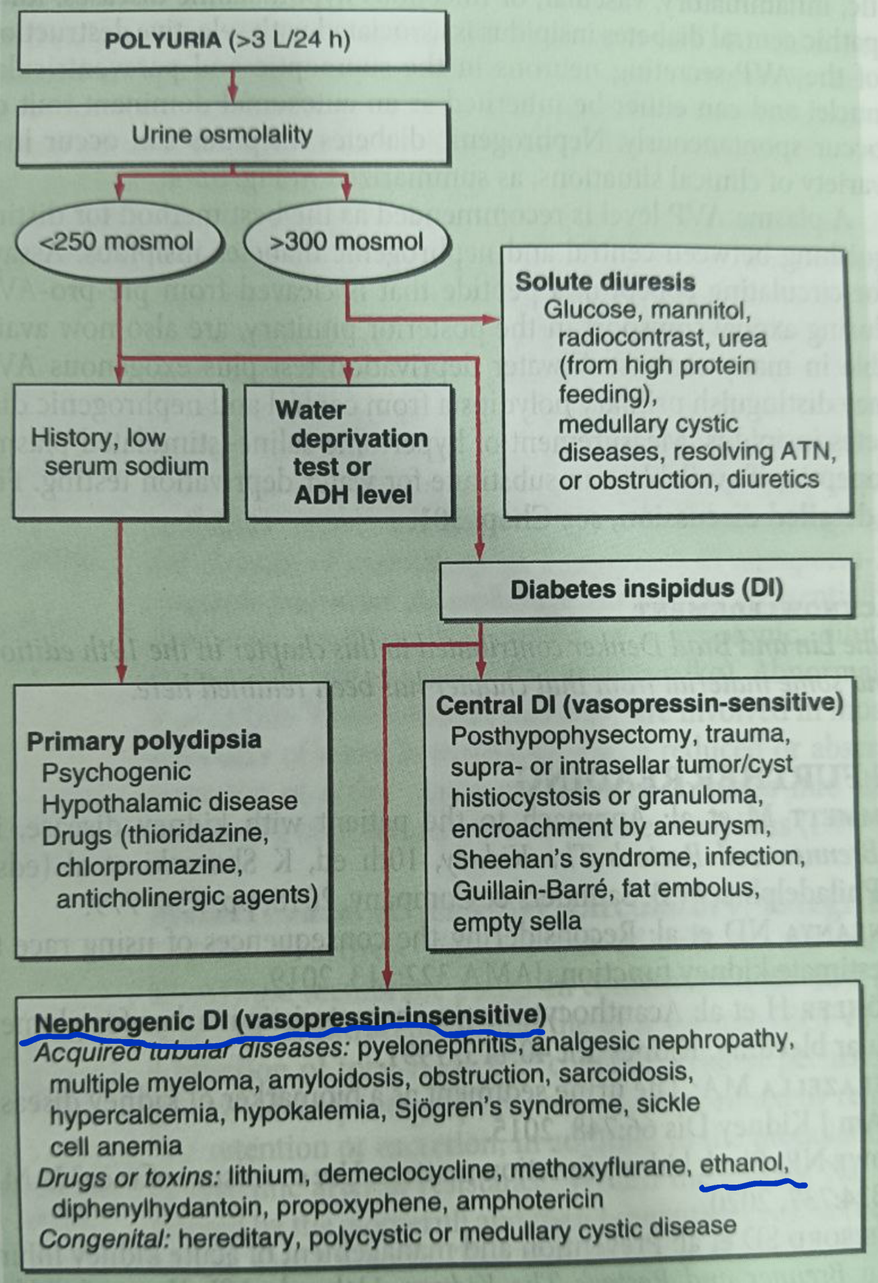

FIGURE 52-4 Approach to the patient with polyuria. ADH, antidiuretic hormone; ATN, acute tubular necrosis.

In our question, there is no information provided about the osmolarity. But if we observe the heading of nephrogenic DI,, Provided in the table we can see that ethanol is one of the cause for nephrogenic DI. And in nephrogenic DI,, the Aquaporin channels are not present on the nephron,, to be specific the DCT. Hence, the correct answer is option C.



A 62 year old women has a four month history of chronic otitis media and mastoiditis Including two episodes of haemoptysis. She smokes 30 cigarettes per day, urine analysis reveals haematuria proteinuria and red cell cast. Chest x-ray reveals cavitating, mass lesion, and evidence of multiple nodules with diffuse alveolar changes. urea and create a nine are elevated. ESR and rheumatoid factor are likewise elevated. What is the most probable diagnosis.

A] bronchial carcinoma
B] good pasture disease
C] Wagner granulomatosis
D] rheumatoid arthritis with typical lung changes
E] tuberculosis

Some extra information to solve the question

CAUSES OF CAVITATING MASS LESION IN LUNGS

MULTIPLE NODULES

1] infective:-granuloma lung abscess/septic emboli,, fungal pneumonia, miliary TB,, pneumonia, chickenpox, pneumonia.
2] malignancy:-metastasis broncoalveolar cell cancer,, lymphoma Kaposi Sarcoma,,mycosis fungoides
3] auto immune disease:-RA nodules wagoners granulomatosis
4] vascular:-AVM ,,pulmonary infarction.
5] other:-Sarcoidosis silicosis LCH

Causes of military nodules :-TB histoplasmosis metastasis sarcoidosis silicosis

Causes of solitary nodule of lung

1] previous infection
2] bronchial carcinoma, metastasis, organising pneumonia, hamartoma
3] abscess, RA nodule,wegener granulomatosis, carcinoid, sarcoid granuloma.
4] hydatid cyst ,,amyloid

Causes of hemoptysis

1] infection:-pneumonia, lung, abscess, acute bronchitis,bronchiectesis,, TB, aspergilloma.

2] neoplastic:-bronchial carcinoma, metastasis
3] vascular:-pulmonary embolism, mitral stenosis,, pulmonary edema, SLE, Wagners granulomatosis, GOODPASTURE syndrome.

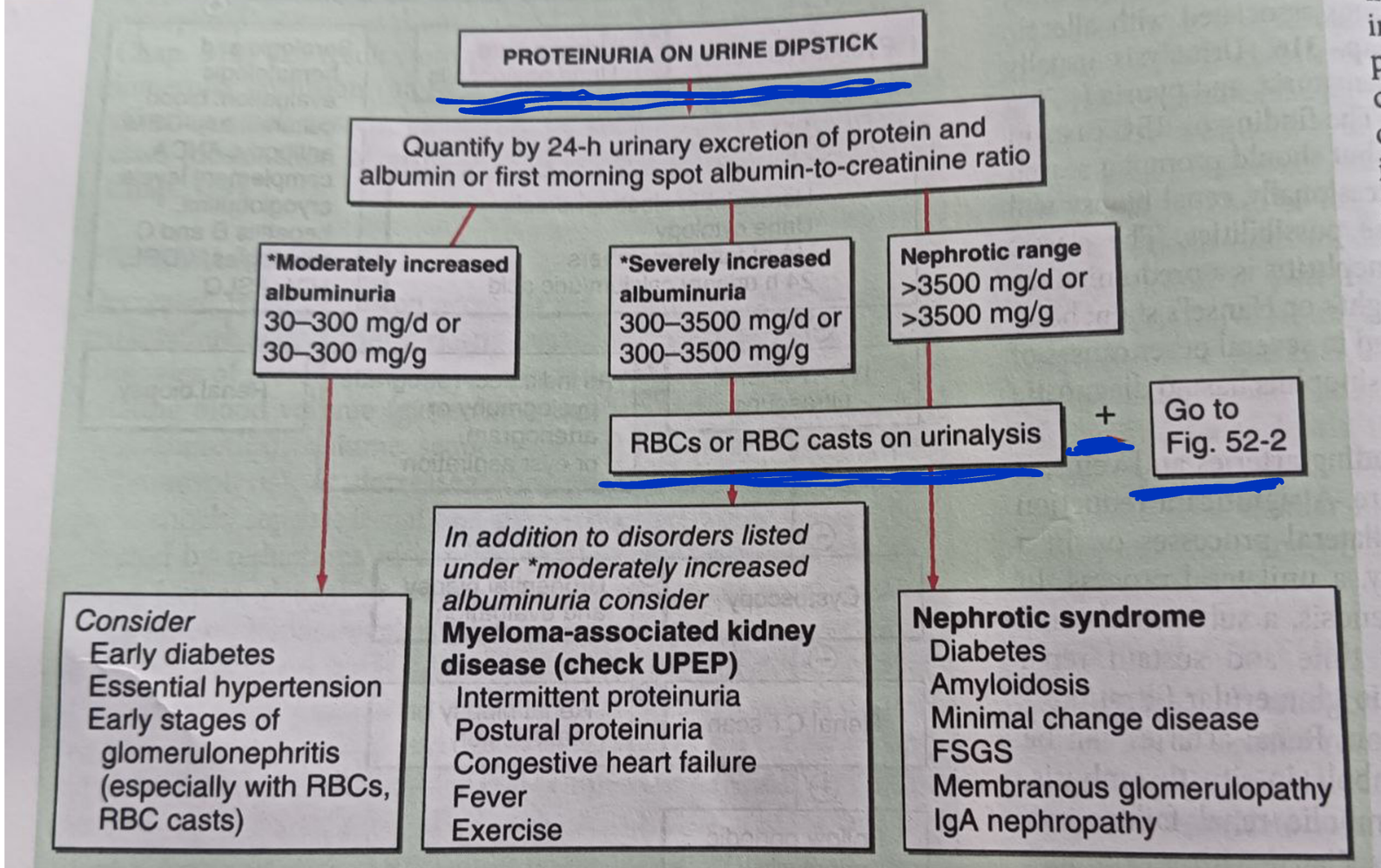

FIGURE 52-3 Approach to the patient with proteinuria. Investigation of proteinuria is often initiated by a positive dipstick on routine urinalysis. Conventional dipsticks detect predominantly albumin and provide a semiquantitative assessment (trace, 1+, 2+, or 3+), which is influenced by urinary concentration as reflected by urine specific gravity (minimum, <1.005; maximum, 1.030). However, more exact determination of proteinuria should employ a spot morning protein/creatinine ratio (mg/g) or a 24-h urine collection (mg/24 h). FSGS, focal segmental glomerulosclerosis; RBC, red blood cell; UPEP, urine protein electrophoresis.

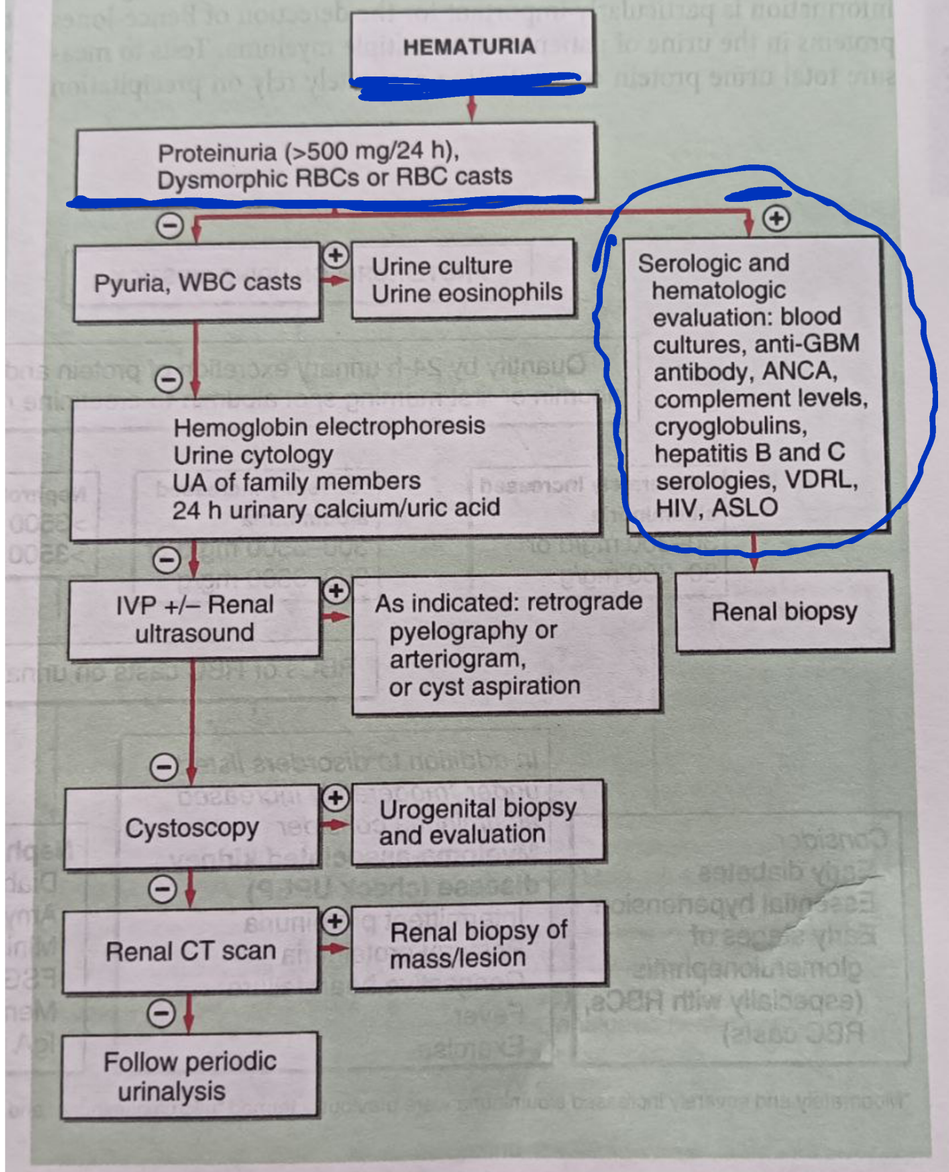

FIGURE 52-2 Approach to the patient with hematuria. ANCA, antineutrophil cytoplasmic antibody; ASLO, antistreptolysin O; CT, computed tomography; GBM, glomerular basement membrane; IVP, intravenous pyelography; RBC, red blood cell; UA, urinalysis; VDRL, Venereal Disease Research Laboratory; WBC, white blood cell.

Let’s pick up the case with proteinuria . See the table named approach to proteinuria.I have underlined that if proteinuria is present and along with it if red cell and or red cell casts are also present then refer the hematuria table. Again see the underlined data.wegner being one of the possibility. Now see differentials of cavitatory lung nodules.there are RA nodules,,wegener,, and bronchial CA. Bronchial ca can’t be there as there is no weight loss in history.there can’t be RA as it is not associated with otitis media. Wegner is the diagnosis as it causes URTI.



A 28-year-old male named Alex is diagnosed with CKD, the cause of which is unknown. he is currently on dialysis,,after seven months of dialysis, he requires a kidney transplant. 10 months post transplant, his kidney function test have fallen dramatically from creatinine of 150 to 900 umol/l,, on rooting clinical visits, four weeks apart. The kidney biopsy is shown ahead. On immune fluorescent, there is linear binding of IgG to the glomerular basement membrane. the serum anti GBM titres are negative. What is the diagnosis?

renal biopsy image

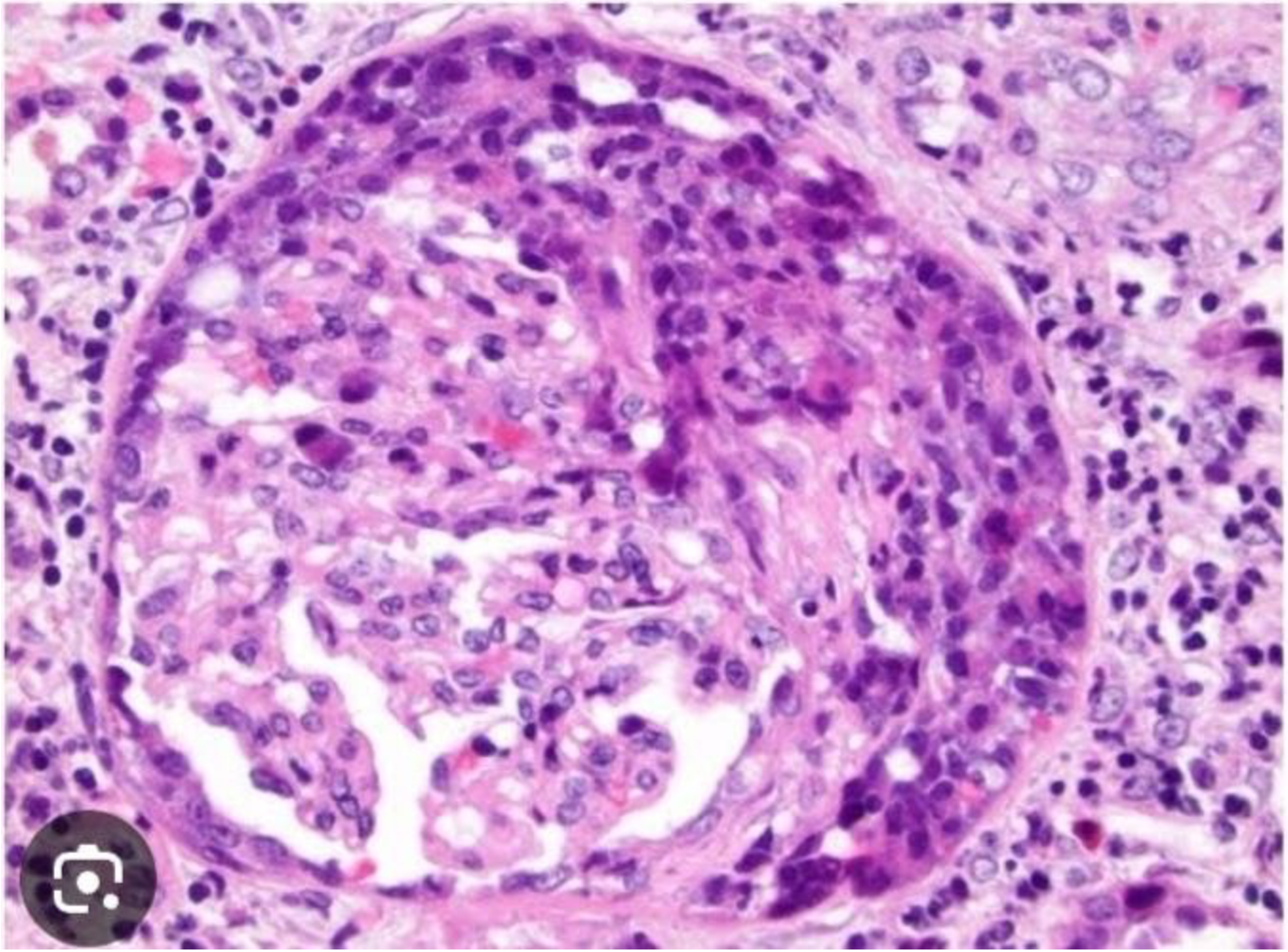

I HAVE ANSWERED THIS QUESTION IN A LENGHTY MANNER SO THAT U CAN UNDERSTAND IT,,,JUST READ THE ANSWER WITH PATIENCE AS THE QUESTION IS VERY NICE AND THE SOLUTION IS VERY BEAUTIFUL

ANSWER!!!

POST TRANSPLANT THERE IS AZOTEMIA THAT SUGGESTS AKI. SINCE THERE IS NO HYPOVOLEMIC FACTOR PRESENT ,,IT CANT BE PRERENAL FAILURE,,THERE ARE NO URINARY TRACT OBSTRUCTION SYMPTOMS AND NO FLANK PAIN SO POSTRENAL FAILURE NOT LIKELY. SO IT IS INTRARENAL FAILURE.KIDNEY BIOPSY SHOWS CRSCENTS,, SO ITS RPGN.SINCE THERE IS LINEAR STAINING OF GBM OF DONOR KIDNEY,,THIS SUGGESTS GOODPASTURE DISEASE.

SO THERE IS ANTIBODY IS PRESENT IN BLOOD OF RECEPIENT THAT REACTED AGAINST GBM OF DONOR KIDNEY,,SO WHAT COMES TO OUR MIND THAT ANTIBODY MUST BE DIRECTED TO ALPHA3 CHAIN OF COLLAGEN OF GBM. IF THIS WAS SO THEN THE ANTI GBM ANTIBODY ESSAY HAS TO BE POSITIVE BUT THE SERUM ANTIBODY TITRES ARE NEGATIVE. NOW LET ME EXPLAIN U A FACT.

THE TEST FOR DETECTION OF SERUM ANTI GBM ANTIBODY IS BASED ON APLHA3 CHAIN ANTIGEN. IN ANTI GBM DISEASE THE ANTIBODY IS AGAINST ALPHA3 CHAIN SO THE TEST COMES OUT TO BE POSITIVE.BUT IN OUR QUESTION THERE IS LINEAR BINDING TO GBM BUT THE TEST IS NEGATIVE,, THIS IMPLIES THAT THE ANTIBODY DID BIND TO GBM OF THE HEALTHY DONOR KIDNEY,,BUT NOT WITH ITS ALPHA 3 CHAIN.THIS MEANS THAT THE ANTIBODY HAD IMMUNOTOLERANCE(THE ABILITY TO IDENTIFY SELF ANTIGENS AND NOT PRODUCING Ab TO THEM]

THE ANTIBODY HAD IMMUNOTOLERANCE FOR ALPHA3 CHAIN OF ORIGINAL KIDNEY OF RECEPIENT.HENCE IT IS NOT MADE AGAINST ALPHA3 CHAIN,,, SO THE TEST CAME OUT TO BE NEGATIVE.THE OTHER ALPHA CHAIN REMAINING IN THE GBM ARE 4 AND 5.NOW ITS OBVIOUS THAT ONE OF THESE ALPHA CHAINS HAVE TO BE ABSENT IN THE GBM OF THE ORIGINAL KIDNEY OF THE RECEPIENT. AND SUCH A CONDITION IN WHICH ALPHA 4/5 CHAIN IS ABSENT CONGENITALLY IS ALPORT SYNDROME.

SINCE IN ALPORT SYNDROME ALPHA 5 CHAIN IS ABSENT IN GBM BY BIRTH,,SO THE BODY[IMMUNE SYSTEM]OF RECEPIENT AFTER COMING IN CONTACT WITH THE ALPHA 5 CHAIN OF HEALTHY KIDNEY OF DONOR WILL SENSE THE ALPHA 5 CHAIN AS FOREIGN AND MAKE ANTI GBM ANTIBODY AGAINST IT.AND SINCE THE TEST FOR ANTI GBM ANTIBODY IS BASED ON ALPHA3 CHAIN,, THE TITRE FOR ANTI GBM ANTIBODY [WHICH IS DIRECTED AGAINST ALPHA5 CHAIN],,WILL BE VERY LOW/NEGATIVE.SO THE ANSWER IS ALPORT SYNDROME.HOPE U GOT IT.



28 YEAR OLD MAN WHO GET A RENAL TRANSPLANT 4 MONTHS EARLIER NOW PRESENTS WITH FEVER VISION PROBLEMS AND DIARRHEOA FOR 7 DAYS.BP IS 135/82,,PULSE IS 84 REGULAR.FUNDOSCOPY IS SHOWN AHEAD.WHAT IS THE DIAGNOSIS. WHAT PATHOLOGICAL FINDIND IS ASSOCIATED WITH THE DIAGNOSIS.

THE FUNDOSCOPY SHOWS PIZZA PIE RETINITIS CHARACTERISTIC OF CMV. CMV GETS ACTIVE IN PT OF RENAL TRANSPLANT,BONE MARROW TRANSPLANT ETC. DRUG OF CHOICE WILL BE GANCYCLOVIR.THE PATHOLOGICAL FINDING WITH CMV IS OWL EYE APPEARANCE AS SHOWN AHEAD WHICH IS ALSO SEEN IN HODGKIN LYMPHOMA.

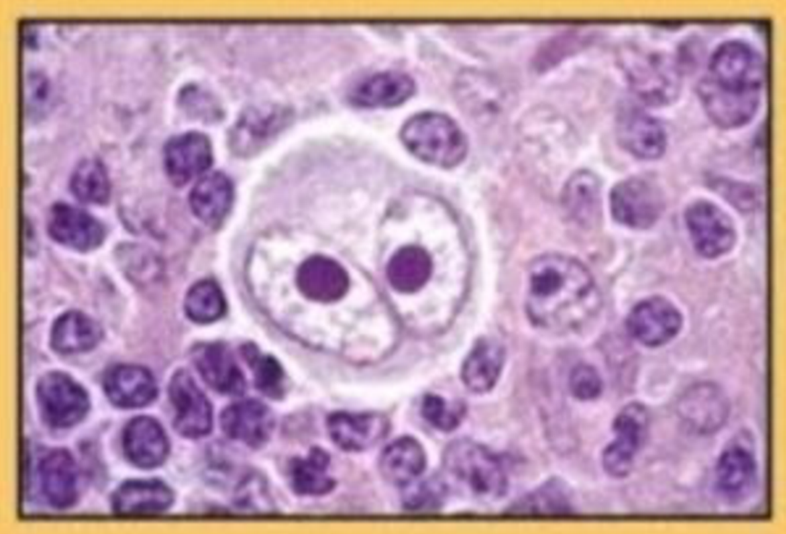

VS

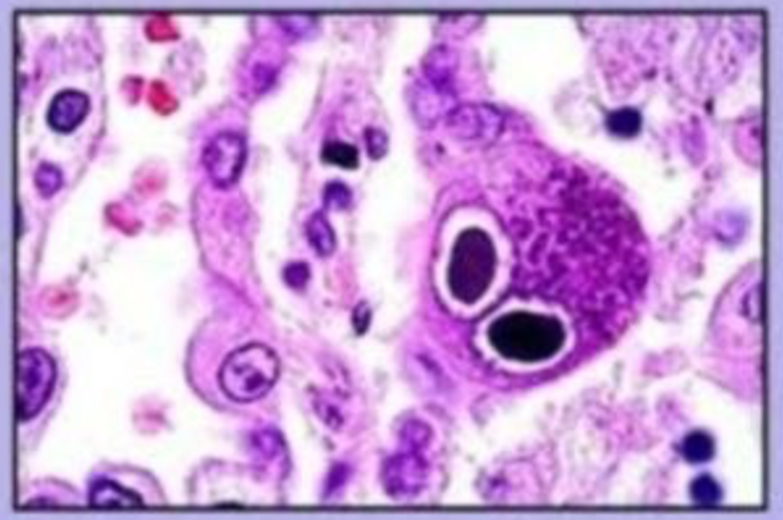

Reed sternberg cells	Cytomegalovirus
Eosinophilic prominent Nuclei	Basophilic nuclear & Cytoplasmic inclusions
Owl eye appearance Found in Hodgkin's Lymphoma	Owl eye appearance Found in cytomegalovirus



A 23 year old athlete runner presented with ankle swelling that had been getting worse over the previous few weeks.He thought that this was related to his workout and running activities so he took several types of analgesics.on examination BP was 132/80. And there was bilateral ankle edema.There was an ejection systolic murmur at the left sternal edge.jvp normal,chest clear.urieanalysis showed blood 4+ and protein 3+.

Creatinine high
serum albumin low
UACR high
c3,c4 are normal
CRP normal
ANCA negative.

A]PSGN

B]IgA NEPHROPATHY

C]INFECTIVE ENDOCARDITIS

D]INTERSTITIAL NEPHRITIS

E]RENAL PAPILLARY NECROSIS

DIAGNOSIS????

SINCE THERE IS NO HISTORY OF ANY SORE THROAT OR IMPETIGO,, AND COMPLEMENT ARE ALSO NORMAL SO PSGN IS LESS LIKELY.OPTION A WRONG

IN INFECTIVE ENDOCRADITIS COMPLENT C3 IS LOW,,BUT HERE ITS NORMAL AND THERE IS NO FEVER SO IE IS LESS LIKELY.OPTION C WRONG

IN INTERSTITIAL NEPHRITIS URINANALYSIS SHOULD SHOW WBC CASTS,, BUT NOT PRESENT HERE,,SO AIN IS LESS LIKELY,OPTION D WRONG

SINCE THERE IS HISTORY OF ANALGESIC USE THERE IS POSSIBILITY OF RENAL PAPILLARY NECROSIS AND NOT IgA NEPHROPATHY. THEN WHAT ABOUT THE ANKLE EDEMA AND PROTEINURIA,,HEMATURIA??

LINE FROM HARRISON:-20-30% PATEINT OF RENAL PAPILLARY NECROSIS HAVE PROTEINURIA,, AND IF IT IS OF NEPHROTIC RANGE,,THEN IT MAY CAUSE RENAL FAILURE AS IN OUR CASE.RENAL PAPILLARY NECROSIS ALSO CAUSES HEMATURIA.

TABLE 16.1 Hypocomplementemia in Glomerular Disease

Pathways Affected	Complement Changes	Glomerular Disease	Nonglomerular Disease
Classical pathway activation	C3↓, C4↓, CH50↓	Lupus nephritis (especially class IV) Cryoglobulinemia Membranoproliferative GN type 1	
Alternative pathway activation	C3↓, C4 normal, CH50↓	Poststreptococcal GN GN associated with other infection[a] (e.g., endocarditis, shunt nephritis) HUS	Atheroembolic renal disease
	plus C3 nephritic factor	Dense deposit disease	
Reduced complement synthesis	Acquired		Hepatic disease Malnutrition
	Hereditary C2 or C4 deficiency Factor H deficiency	Lupus nephritis Familial HUS Dense deposit disease	

GN with visceral abscesses is generally associated with normal or increased complement (elevations occur because complement compone
cute-phase reactants).

CH50, 50% hemolyzing dose of complement; *GN*, glomerulonephritis; *HUS*, hemolytic uremic syndrome.

Goodpasture Syndrome	Lung hemorrhage	Anti–glomerular basement membrane antibody (occasionally ANCA present)
Vasculitis		
Granulomatosis with polyangiitis	Upper and lower respiratory tract involvement	Mostly PR3 ANCA
Microscopic polyangiitis	Multisystem involvement	Mostly MPO ANCA
Pauci-immune crescentic glomerulonephritis	Renal involvement only	MPO or PR3 ANCA
Immune Complex Disease		
Systemic lupus erythematosus	Other multisystem features of lupus	Antinuclear antibody, anti–double-stranded DNA antibody, C3↓, C4↓
Poststreptococcal glomerulonephritis	Pharyngitis, impetigo	Antistreptolysin titer, streptozyme antibody C3↓, C4 normal
IgA nephropathy; IgA vasculitis (HSP)	Characteristic rash ± abdominal pain in IgA vasculitis	Serum IgA↑ (30%) C3 and C4 normal
Endocarditis	Cardiac murmur; other systemic features of bacteremia	Blood cultures ANCA (occasionally) C3↓, C4 normal

Note the overlap between these diseases and those in Table 16.5. A number of glomerular diseases may present with either nephritic syndrome or RPGN.

ANCA, Antineutrophil cytoplasmic antibody; *HSP*, Henoch-Schönlein purpura; *IgA*, immunoglobulin A; *MPO*, myeloperoxidase; *PR3*, proteinase 3; *RPGN*, rapidly progressive glomerulonephritis.

Renal Papillary Necrosis

Causes:

P - Pyelonephritis
O - Obstruction
S - Sickle cell disease
T - TB
C - Cirrhosis
A - Analgesic abuse
R - Renal vein thrombosis
D - Diabetes mellitus
S - Systemic vasculitis



36-year-old prostitute from Australia presented with a four week. History of peripheral edema and shortness of breath. She is a HIV, positive patient and recently started on highly active antiretroviral therapy. On examination, the BP is 138/74.

Hb low
Platelets low
S.sodium low
S.potassium normal
S.urea high
S.creatinine high
EGFR low
S.albumin low
Urine acr 375[normal less then 30]
C3,C4, normal.

A] focal segmental glomerulosclerosis

B] INTERSTITIAL NEPHRITIS

C]MEMBRANOUS NEPHRITIS

D]MCD

E]TTP

IN THIS QUESTION THERE IS LOW PLATELET AND LOW HAEMOGLOBIN SO U MIGHT THINK IT AS TTP,,, BUT IN TTP COMPLEMENT C3 IS LOW,,BUT HERE ITS NORMAL.SO ITS NOT TTP

TABLE 16.1 Hypocomplementemia in Glomerular Disease

Pathways Affected	Complement Changes	Glomerular Disease	Nonglomerular Disease
Classical pathway activation	C3↓, C4↓, CH50↓	Lupus nephritis (especially class IV) Cryoglobulinemia Membranoproliferative GN type 1	
Alternative pathway activation	C3↓, C4 normal, CH50↓	Poststreptococcal GN GN associated with other infection[a] (e.g., endocarditis, shunt nephritis) HUS	Atheroembolic renal disease
	plus C3 nephritic factor	Dense deposit disease	
Reduced complement synthesis	Acquired		Hepatic disease Malnutrition
	Hereditary C2 or C4 deficiency Factor H deficiency	Lupus nephritis Familial HUS Dense deposit disease	

GN with visceral abscesses is generally associated with normal or increased complement (elevations occur because complement compone

SINCE THERE IS HISTORY OF HIV IN THIS PATIENT AND ACCORDING TO THE OPTION,,, IT FITS INTO EITHER IN MEMBRANOUS NEPHROPATHY OR FSGS AS HIV IS ONE OF THE CAUSE FOR BOTH. BUT GO BACK TO THE THEORY SECTION WHERE I HAVE WRITTEN THAT HIV IS A UNCOMMON CAUSE OF MEMBRANOUS NEPHROPATHY. HENCE ANSWER IS IN FAVOUR OF FSGS. SEE THE TABLE AHEAD.

BOX 19.1 Etiologic Classification of Focal Segmental Glomerulosclerosis

Primary

- Presumably mediated by circulating/permeability factor(s)

Genetic Causes

- (See Chapter 20)

Secondary

Virus Associated

- HIV-1 (HIV-associated nephropathy)
- SARS-CoV-2 (COVID-19 associated nephropathy)
- Parvovirus B19
- CMV
- EBV

Drug Induced

- Interferon
- Pamidronate
- Sirolimus
- Anabolic steroids

Adaptive Changes to Glomerular Hyperfiltration

Reduced Kidney Mass

- Oligomeganephronia
- Very low birth weight (correlating with low nephron endowment)
- Unilateral kidney agenesis
- Kidney dysplasia
- Reflux nephropathy
- Sequela to cortical necrosis
- Surgical kidney ablation
- Any advanced kidney disease with reduction in functioning nephrons

Initially Normal Kidney Mass

- Hypertension
- Atheroemboli or other acute vasoocclusive processes
- Obesity
- Bodybuilders
- Cyanotic congenital heart disease
- Sickle cell anemia

Uncertain Cause



37-year-old man presence to the emergency department, complaining of swelling of his legs, hands, face for four days on examination, he is afebrile with generalised edema office, upper and lower extremities as well as his face. He has scars in a linear pattern on his middle to lower arms, bilaterally. CBC is normal. Total protein is 5.4 milligram per decilitre and albumin 2.8/dL. Urine analysis shows 3+ protein urea without WBC or RBC, which of the following is the diagnosis?.

A]Ab DEPOSITION

B]CARDIOMYOPATHY

C]COCAINE ABUSE

D]HEROINE ABUSE.

URINANALYSIS REVEALED PROTEINURIA 3+,,SERUM ALBUMIN LOW AND ANASARCAPOINTS TO NEPHROTIC SYNDROME.LINEAR SCARS BILATERALLY ON ARMS,,FIT WITH OPTION D] HEROINE.

Causes	Approximate Prevalence (%)[a]	
	Children	Adults
Primary Glomerular Disease		
Membranous nephropathy	3	30
Minimal change disease	75	8
Focal segmental glomerulosclerosis	10	35
Membranoproliferative glomerulonephritis and dense deposit disease[b]	10	10
Other proliferative glomerulonephritides (focal, "pure mesangial," IgA nephropathy)[b]	2	17
Systemic Diseases		
Diabetes mellitus		
Amyloidosis		
Systemic lupus erythematosus		
Drugs (nonsteroidal antiinflammatory, penicillamine, heroin)		
Infections (malaria, syphilis, hepatitis B and C, HIV)		
Malignant disease (carcinoma, lymphoma)		
Miscellaneous (bee-sting allergy, hereditary nephritis)		



A 65 YEAR OLD MAN PRESENTS WITH HYPOTENSION,,VOMITTING DIARRHEA AND LOW URINE OUTPUT. BUN HIGH,,CREAT HIGH,FENA LESS THEN 1%,,AFTER ONE LITRE IV NORMAL SALINE,,URINE OUTPUT IMPROVES ,WHICH FINDING CONFIRMS A PRE RENAL CAUSE FOR AKI.

A]HIGH URINE OSMOLARITY

B]MUDDY BROWN GRANULAR CASTE

C]FENA MORE THAN 2%

D]PERSISTENT OLIGURIA AFTER FLUIDS.

LETS FIRST TRY TO UNDERSTAND TO ELIMINATE OPTION D].

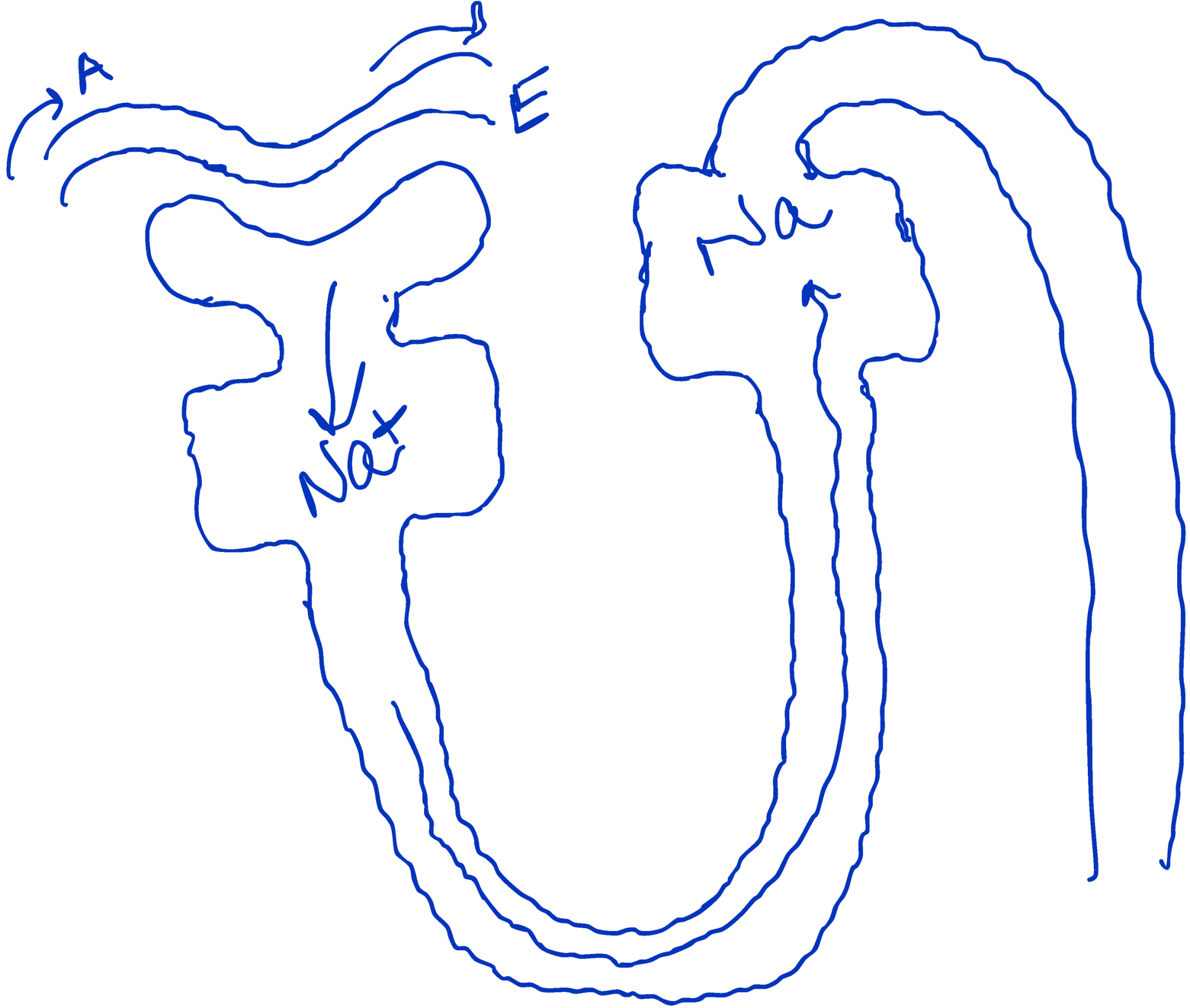
A
E
Na+
Na

IN CASE OF INTRINSIC KIDNEY DISEASE [ATI/ATN],,THERE IS DAMAGE TO PCT,,SO MORE SODIUM WILL BE DILEVERED TO DCT,, SO DCT WILL THINK THAT GFR IS INCREASED,, SO IT WILL DECREASE GFR BY CAUSING CONSTRICTION OF AFFERENT ARTERIOLE[A] KNOWN AS TUBULOGLOMERULAR FEEDBACK.SO NOW,,IF WE GIVE FLUIDS TO PATIENT,GFR WILL NOT INCREASE AS AFFERENT ARTERIOLE IS CONSTRICTED SO FLUID CANT ENTER GLOMERULUS AND FILTRATE.SEE THE DIAGRAM TO VISUALIZE.THIS WILL INCREASE THE PEDAL EDEMA.SO OPTION D] WRONG.

NOW I WILL GIVE TWO TABLES TO ELIMINATE ALL OTHER OPTIONS. CORRECT ANSWER IS OPTION A]

TABLE 4.3 Types of Casts and Their Main Clinical Associations

Cast	Main Clinical Associations
Hyaline	Normal individual; kidney disease
Hyaline-granular	Normal subject; kidney disease
Granular	Kidney disease; AKI associated with ATN
Waxy	Kidney disease with possible functional impairment
Fat	Marked proteinuria, usually but not invariably in the nephrotic range
Erythrocyte	Glomerular hematuria, most frequently because of active proliferative GN; AIN
Leukocyte	AIN; acute pyelonephritis; active proliferative GN
Containing renal tubular epithelial cell (so-called epithelial casts)	AKI associated with ATN; active proliferative GN; nonproliferative GN associated with heavy proteinuria; AIN
Hemoglobin	Glomerular hematuria, most frequently because of active proliferative GN; hemoglobinuria caused by intravascular hemolysis
Myoglobin	AKI because of rhabdomyolysis
Bilirubin	Jaundice caused by increased direct bilirubin
Bacterial, fungal	Bacterial or fungal kidney infections
Crystalline	Crystalline nephropathies
Mixed	According to components present in the cast

AIN, Acute interstitial nephritis; *AKI,* acute kidney injury; *ATN,* acute tubular necrosis; *GN,* glomerulonephritis.

Table 31.10 Urine Indices Used in the Differential Diagnosis of Prerenal Acute Kidney Injury and Acute Tubular Necrosis

Diagnostic Index	Prerenal Acute Kidney Injury	Acute Tubular Necrosis
Fractional excretion of sodium (%)	<1*	>2*
U_{Na} (mmol/L)	<20	>40
Urine creatinine/plasma creatinine ratio	>40	<20
Urine urea nitrogen/plasma urea nitrogen ratio	>8	<3
Urine specific gravity	>1.018	~1.010
Urine osmolality (mOsm/kg H_2O)	>500	~300
Plasma BUN/creatinine ratio	>20	<10-15
Renal failure index, $U_{Na}/(U_{Cr}/P_{Cr})$	<1	>1
Urine sediment	Hyaline casts	Muddy-brown granular casts

*Fractional excretion of sodium (FE_{Na}) may be >1% in prerenal acute kidney injury associated with diuretic use and/or in the setting of bicarbonaturia or chronic kidney disease; FE_{Na} often <1% in acute tubular necrosis caused by radiocontrast media or rhabdomyolysis.

BUN, Blood urea nitrogen; P_{Cr}, plasma creatinine concentration; U_{Cr}, urine creatinine concentration; U_{Na}, urinary sodium concentration.



32 YEAR OLD WOMEN PRESENTS WITH HISTORY OF PAINFUL HANDS IS FOUND TO HAVE HTN PROTEINURIA AND HEMATURIA.PLASMA CREAT IS HIGH.RENAL BIOPSY SHOWS PROLIFERATIVE GLOMERULONEPHRITIS WITH OCCAISONAL CRESCENTS AND IF SHOWS DIFFUSE GRANULAR STAINING FOR IgA,IgM,IgG,C3,C4.

A]PSGN

B] LUPUS NEPHRITIS

C]MEMBRANOUS NEPHROPATHY

D]GOODPASTURE

E] SYSTEMIC VASCULITIS

ANSWER:-THE IF IS SHOWING FULL HOUSE EFFECT SO ANSWER IS OPTION B.

NOW LETS HAVE A LOOK ON RENAL IMMUNOFLOURESCENSE

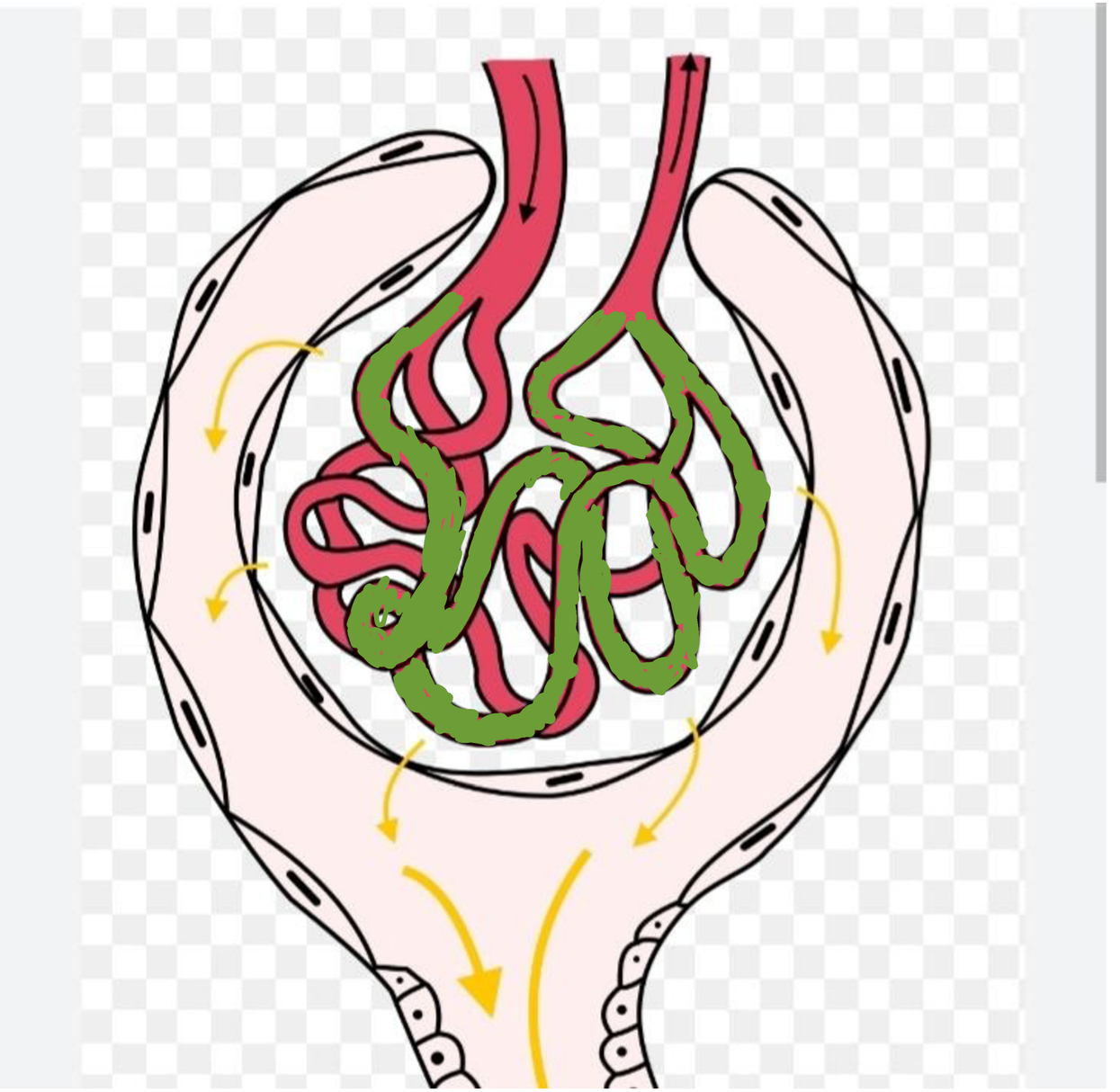

Red = capillary staining

Blue = mesangium

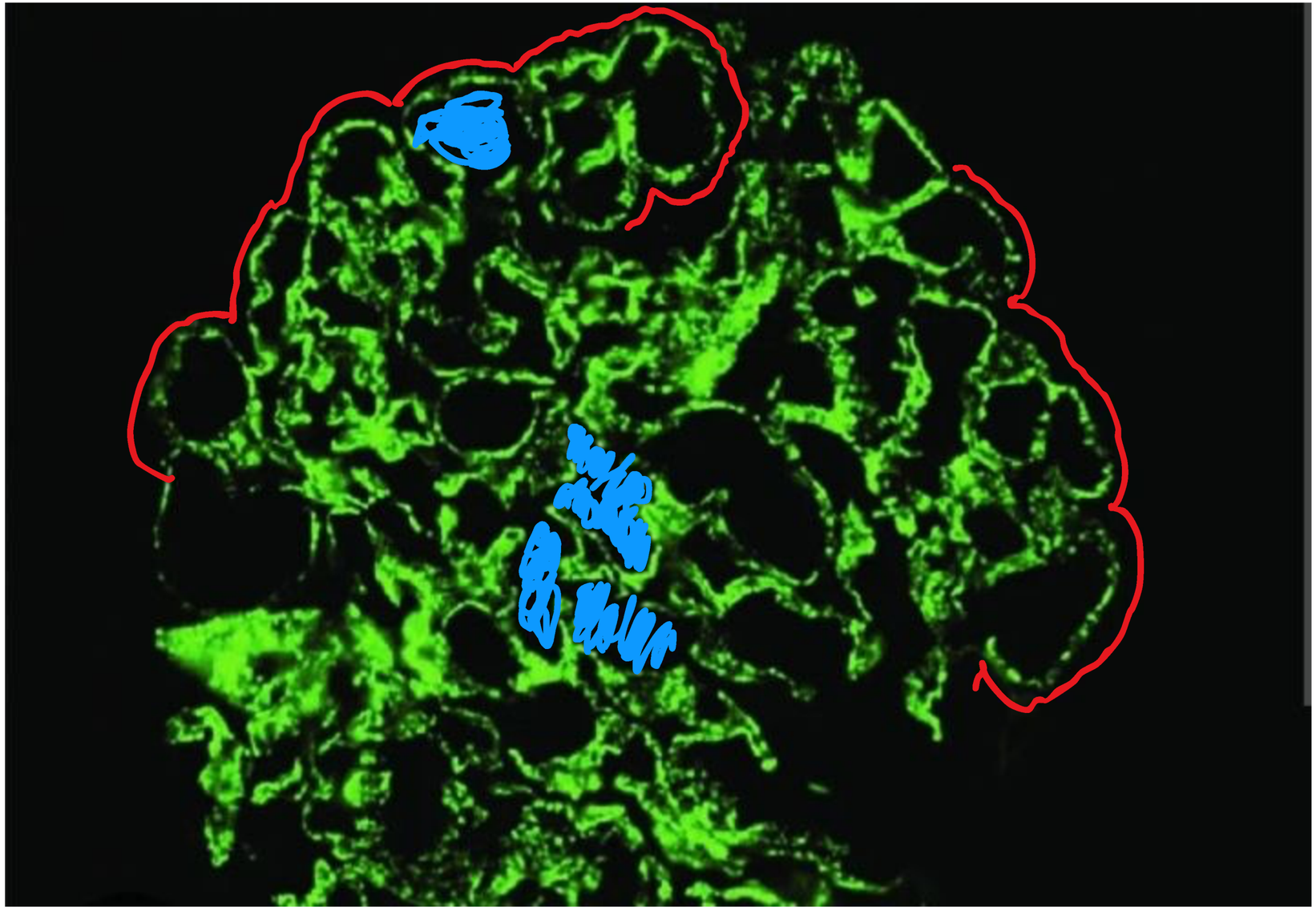

IMMUNOFLOURESCENSE

GENERAL INFORMATION ABOUT IF

ROUTINE ANTIBODY PANEL USED IN IF

IgG

IgA

IgM

kappa light chain lambda light chain

C3,C1q

fibrin/fibrinogen

collagen IV alpha chain

IgG SUBCLASS IDENTIFICATION[IgG1,2,3,4] AND PHOSPHOLIPASE A2 RECEPTOR[PLA2R]STAINING IS USED TO DIAGNOSE PRIMARY MEMBRANOUS NEPHROPATHY.

C4d IS USED TO DIAGNOSE ANTIBODY MEDIATED ACUTE ALLOGRAFT REJECTION.

DISTRIBUTION OF STAINING:-GLOMERULAR [MESANGIAL OR CAPILLARY WALL OR BOTH] OR TUBULOINTERSTITIAL DISEASE

PATTERN OF CAPILLARY WALL STAINING CAN BE LINEAR OR GRANULAR.

NONE 0

MILD +1

MODERATE+2

SEVERE +3

FSGS

SHOWS STAINING FOR IgM AND C3 IN AREAS OF SCLEROSIS[segmental][DIAGRAM A]AND LESS INTENSE STAINING FOR IgM AND C3 IN THE MESANGIUM CAN ALSO BE SEEN[DIAGRAM B]

STAINING CAN BE TO A LESSER EXTENT FOR C1q.

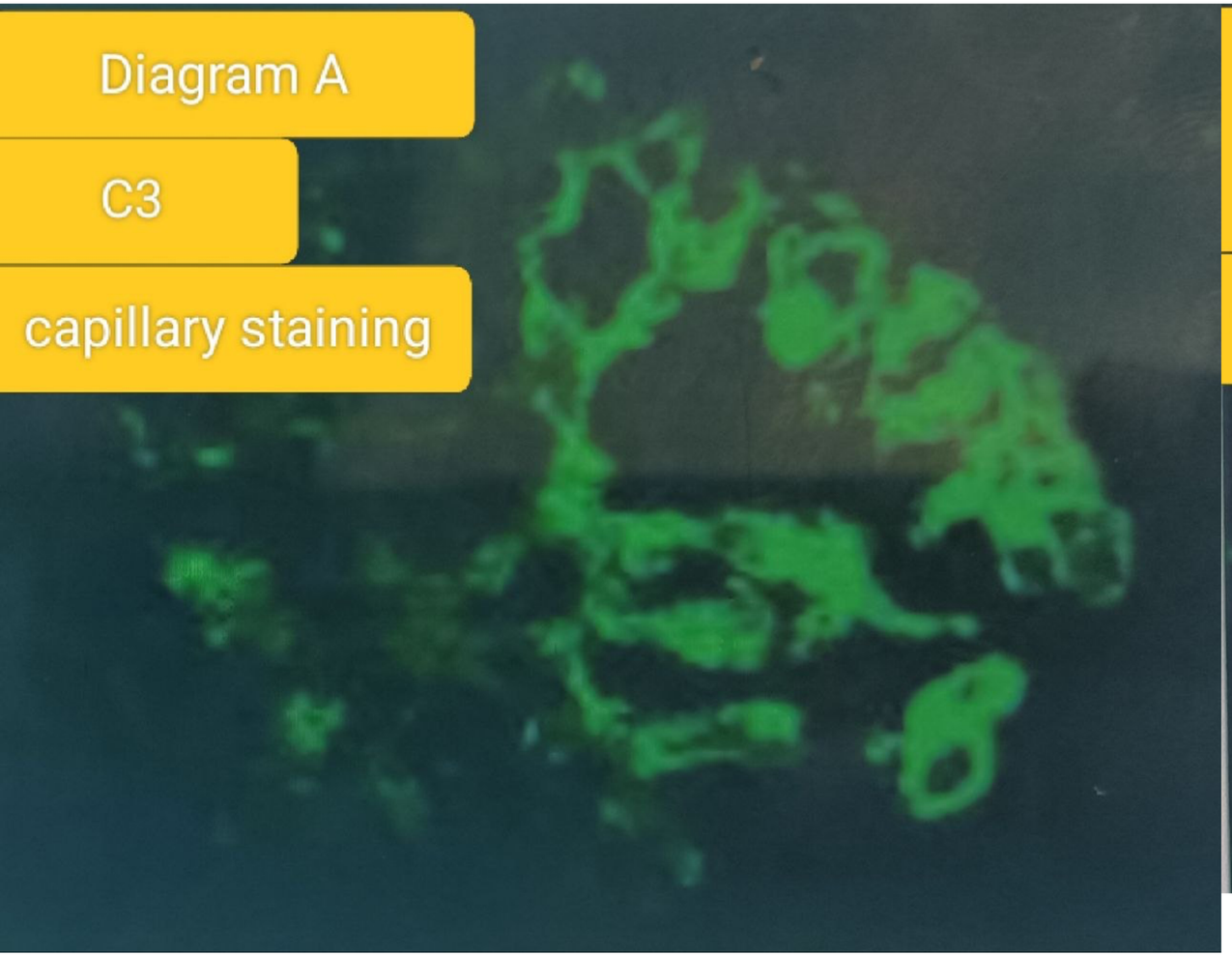
Diagram A
C3
capillary staining

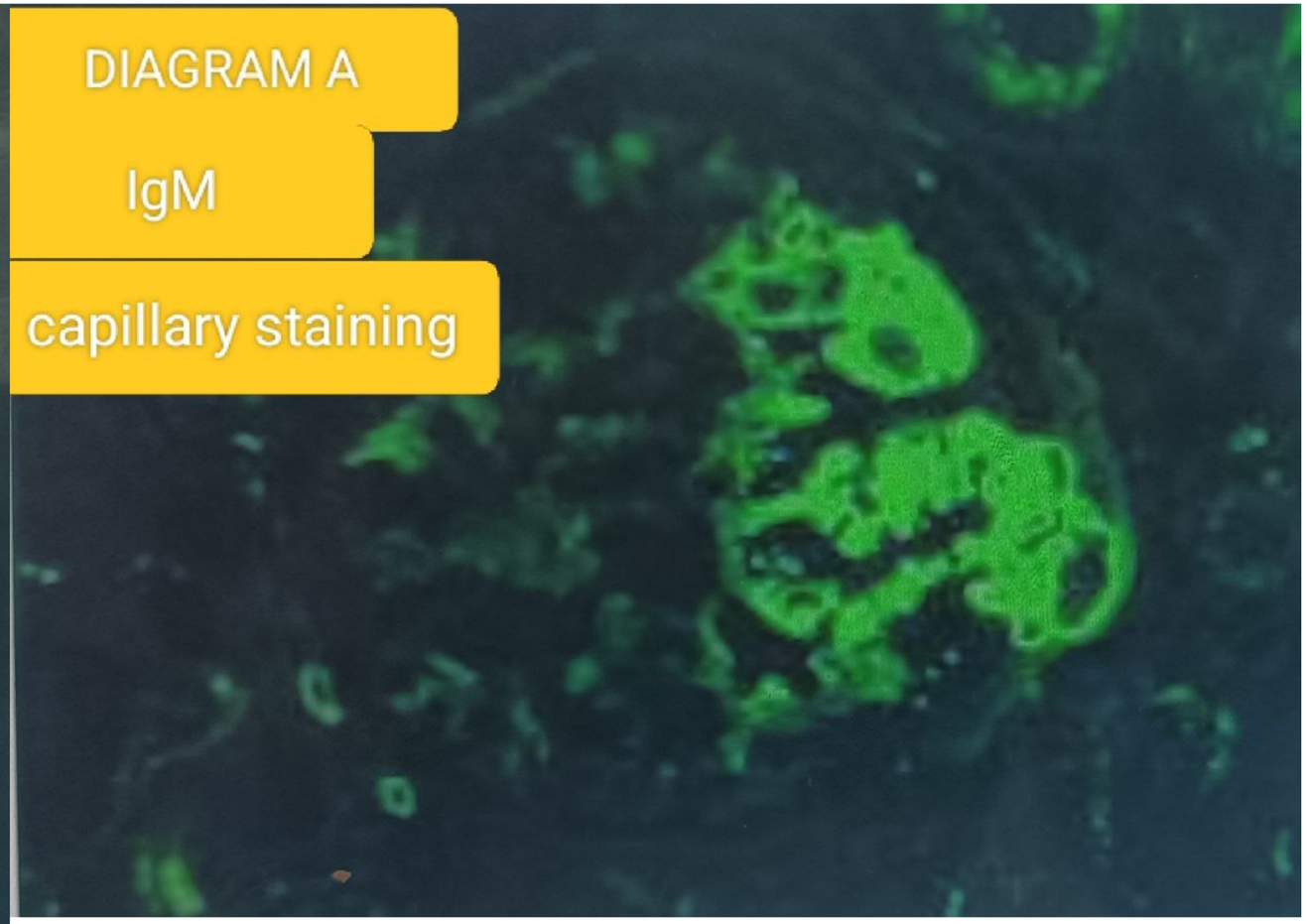
DIAGRAM A
IgM
capillary staining

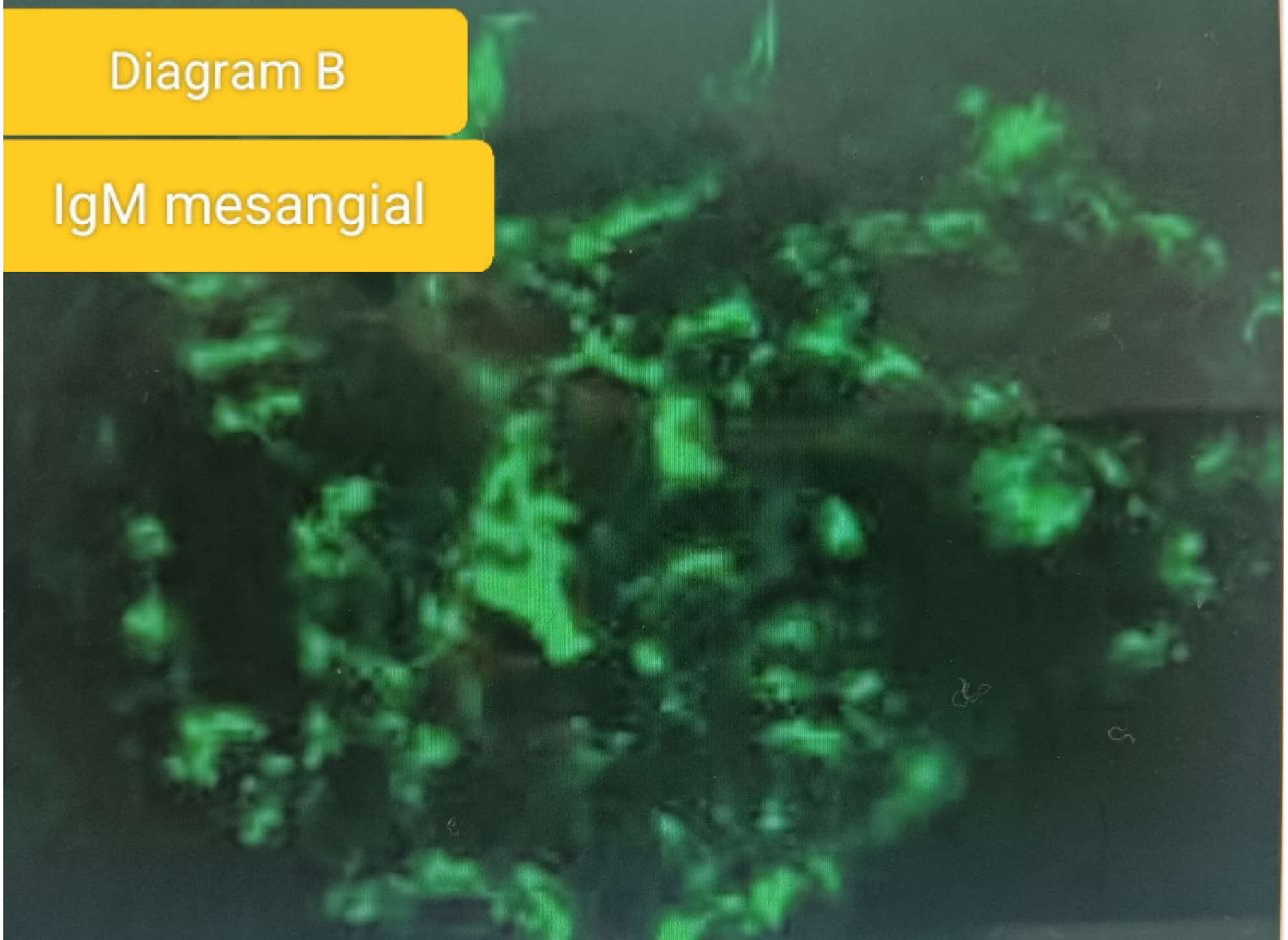
Diagram B
IgM mesangial

MEMBRANOUS NEPHROPATHY

PRIMARY VS SECONDARY,,HOW TO DIFFER?
CAN BE DIFFERENTIATED BY EITHER USING ANTI PLA2R Ab OR BY USING IgG SUBTYPING.

IMMUNE COMPLEX ARE SUBEPITHELIAL IN DEPOSITION ,,HENCE ON IF,, THE STAINING WILL APPEAR TO FOLLOW/WILL BE PARALLEL TO GLOMERULUR BASEMENT MEMBRANE.SO IT WILL BE GRANULAR ,,[IgG STAINING INVARIABLE]

ANTI-PLA2R Ab[IgG SUBCLASS IgG4] POSITIVE IN PRIMARY MEMBRANOUS NEPHROPATHY. IgG1 ALSO FOUND,,ALONG WITH SMALL QUANTITIES OF IgG2 IgG3.

RECURRENT MEMBRANOUS NEPHROPATHY[NOT DE NOVO]IN ALLOGRAFT REJECTION HAS IgG4 STAINING.

IgG1 staining seen in mercury exposure or malignancy related membranous nephropathy

IN MEMBRANOUS NEPHRITIS DUE TO LUPUS,,STAINING IS POSITIVE FOR IgA,IgM,igG,1,2,3 and light staining for IgG4,C1q,C3.THIS FULL HOUSE EFFECT ALSO SEEN IN HBV INFECTION.

PATTERN OF MEMBRANOUS NEPHROPATHY WITH MESANGIAL IgA STAINING [SEE THE NEXT SLIDE FOR IMAGE] IS SEEN IN HBV INFECTION.

IgG granular staining subepithelial

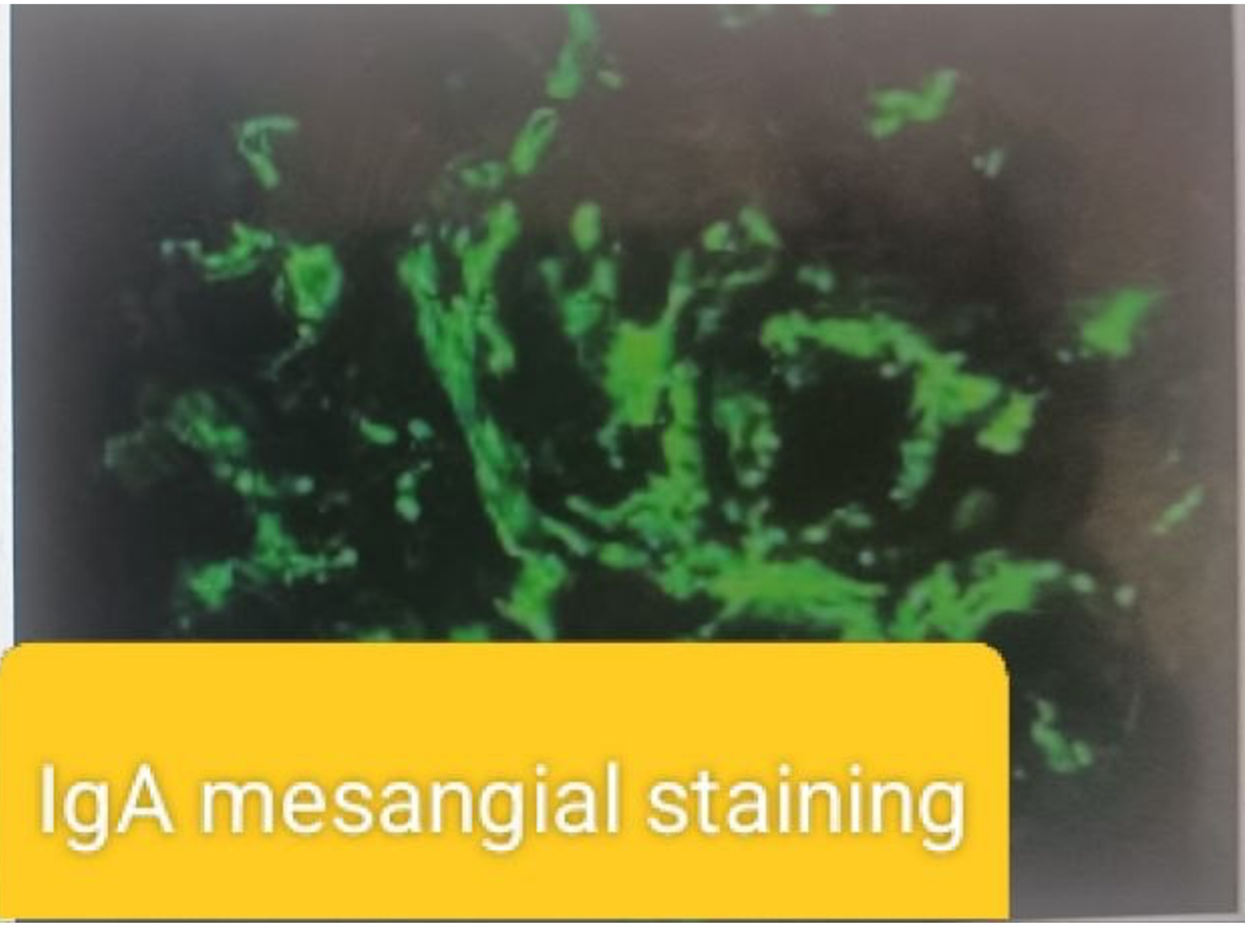
IgA mesangial staining

DEPOSITION OUTSIDE GLOMERULUS IN MEMBRANOUS NEPHROPATHY Eg,in TUBULES SUGGESTS SECONDARY FORM OF DISEASE.

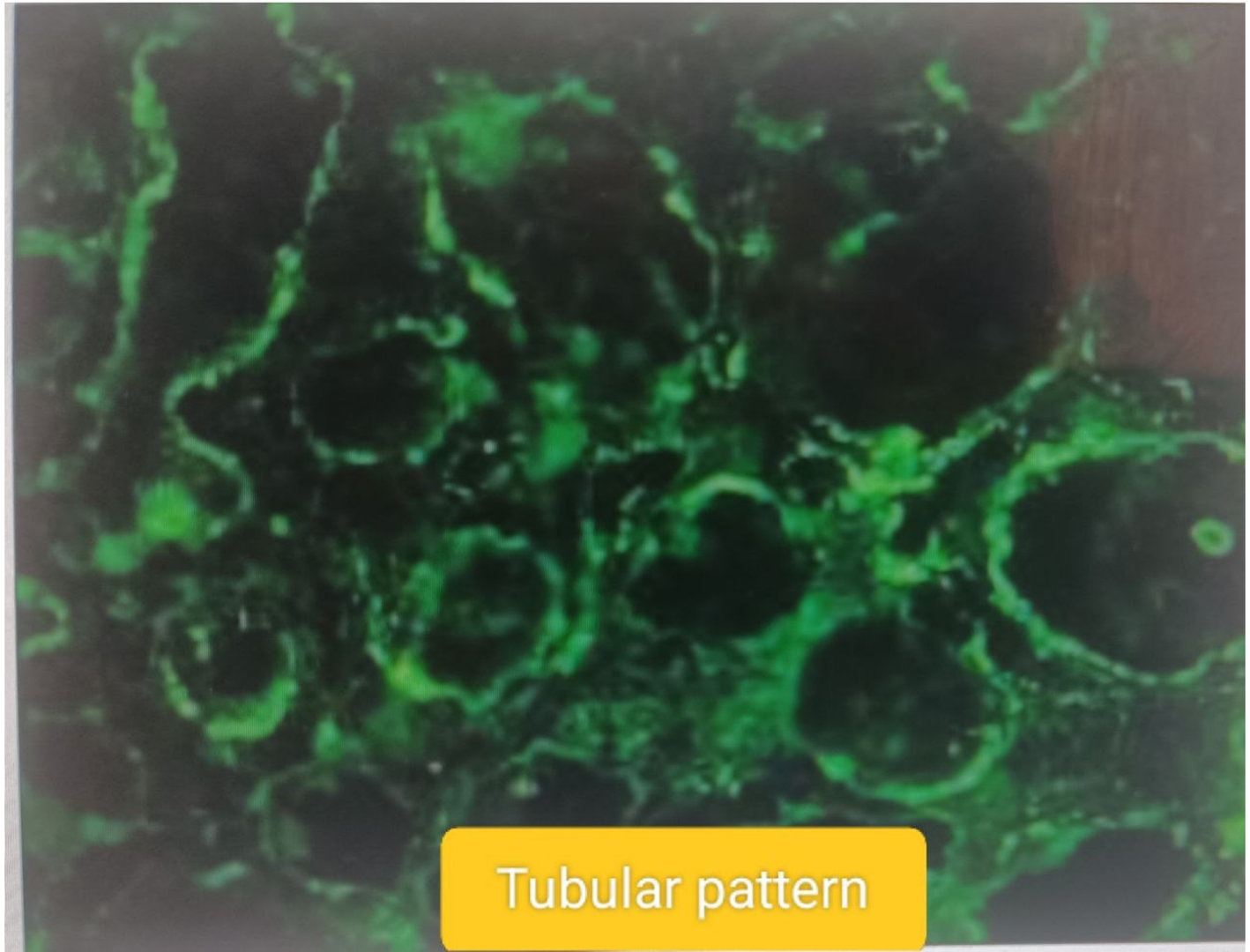

MPGN

MPGN-1:-C3 AND IgG + WITH/WITHOUT IgM AND C1.

MPGN-3:-SAME AS MPGN-1

MPGN 2:-ONLY C3[DENSE DEPOSIT DISEASE]

PSGN [SEE IMAGES AHEAD]

1]GARLAND TYPE IF:-PERIPHERAL CAPILLARY LOOPS STAIN BY IgG AND C3,,MEANGIUM EMPTY.SEEN IN ACUTE GN WITH SEVERE PROTEINURIA.

2]STARRY SKY PATTERN:-IRREGULAR DEPOSIT OF IgG AND C3 IN CAPILLARY WALL AND MESANGIUM.SEEN IN EARLY CASES.

3]MESANGIAL:-IgG and C3[mainly] IN MESANGIUM WITH CAPILLARIES EMPTY.

SOMETIMES IgA GRANULAR DEPOSITION MAY BE FOUND

C3 mesangial deposits

mesangial deposits

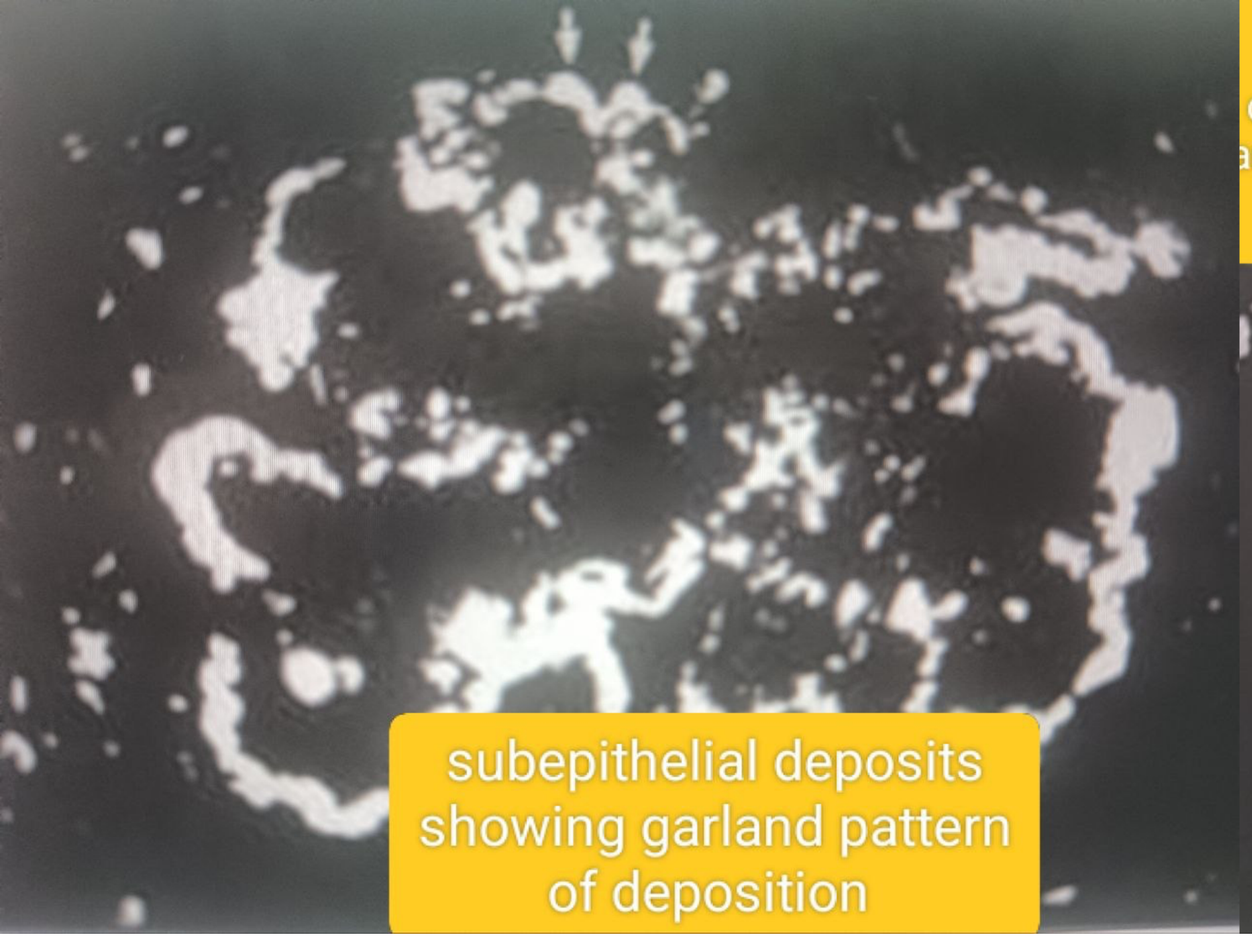
subepithelial deposits showing garland pattern of deposition

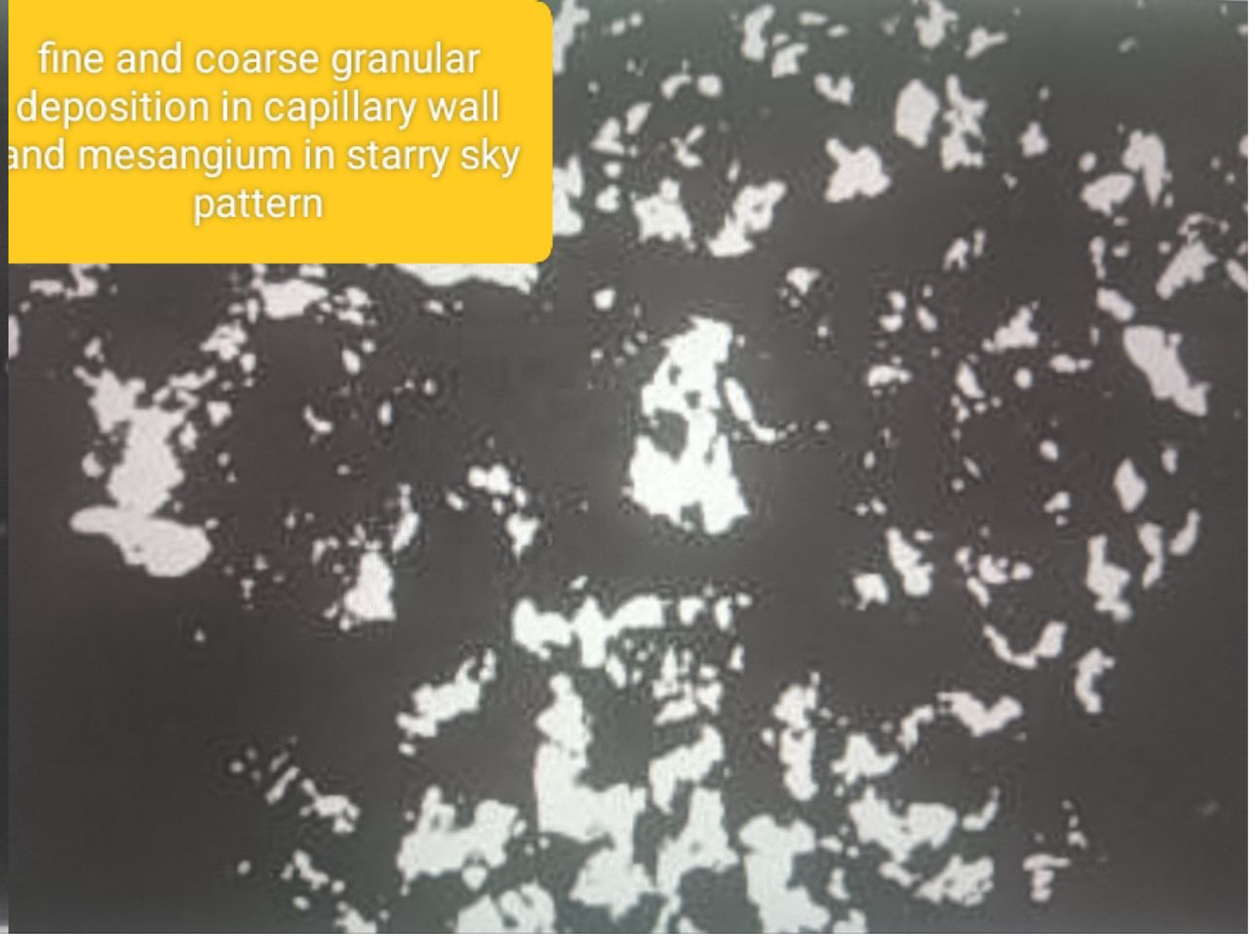
fine and coarse granular deposition in capillary wall and mesangium in starry sky pattern

IgA NEPHROPATHY

MESANGIAL STAINING FOR IgA1 WITH OR WITHOUT IgM,IgG, AND ALMOST ALWAYS WITH POSITIVE STAINING FOR C3.

FIBRINOGEN POSITIVITY,,,ALSO FOUND IN CRESCENTIC GN,,STAINS POSITIVE IN AREA OF CRESCENT.

normal glomerulus

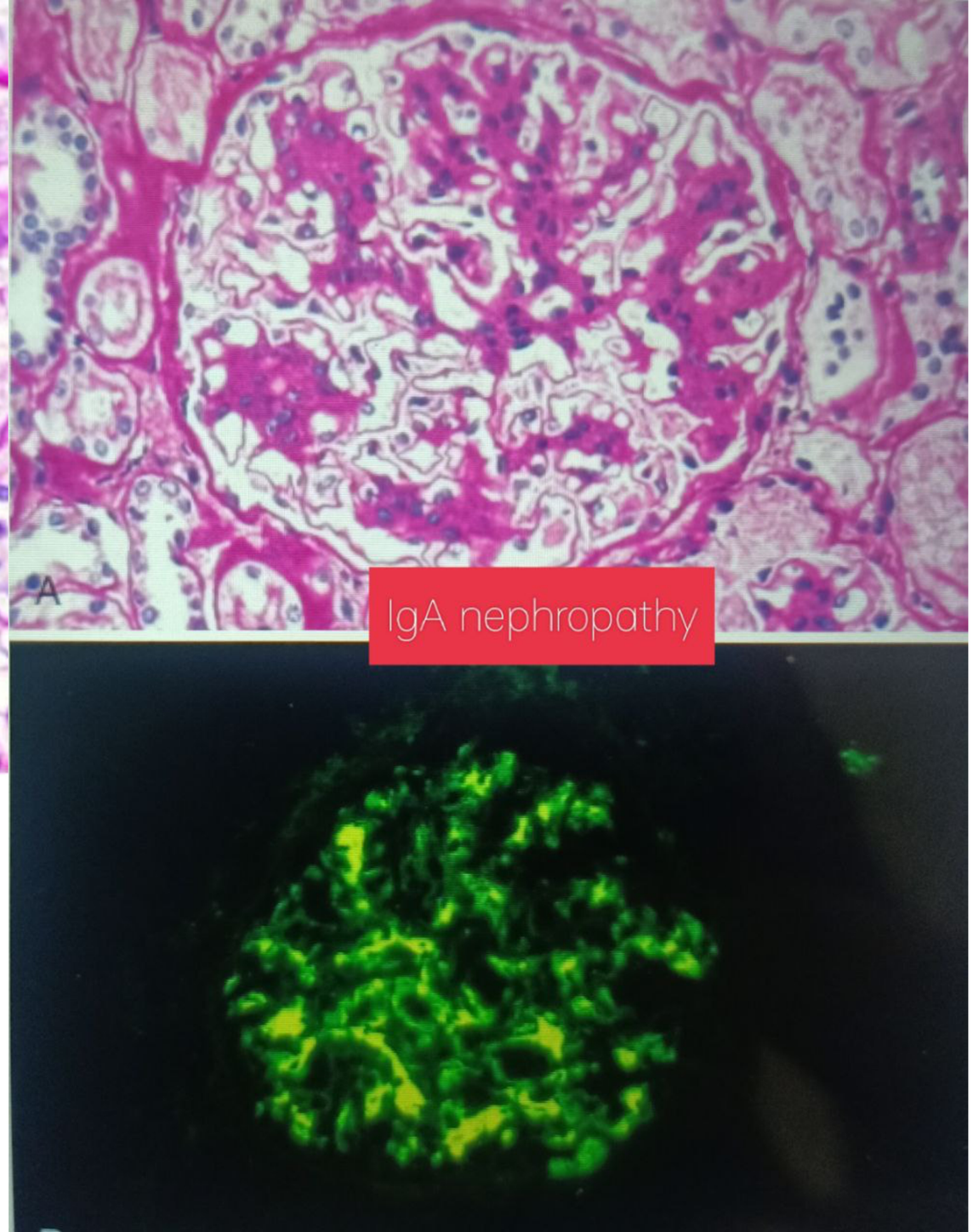
A
IgA nephropathy

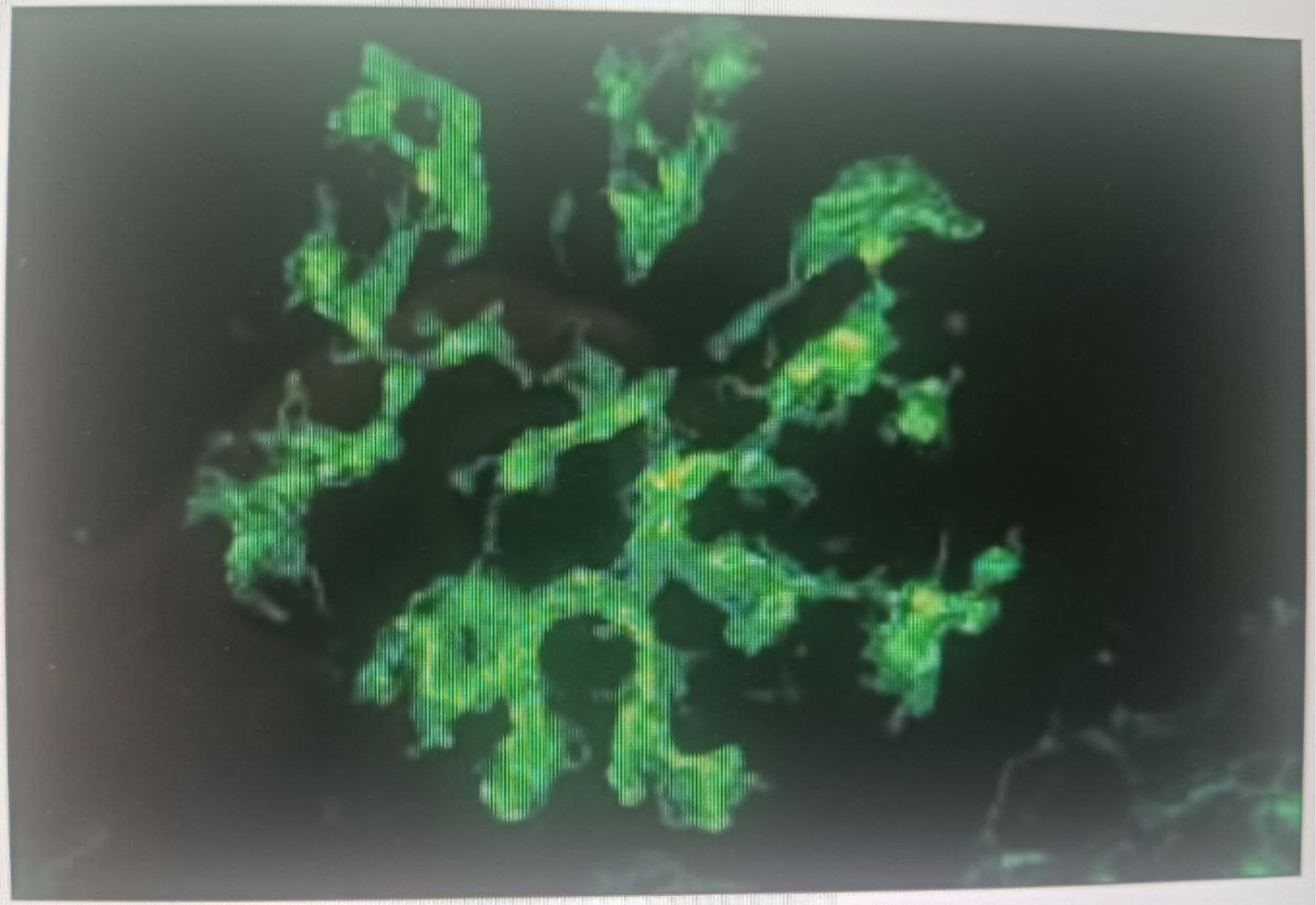

FIGURE 12.18 IgA nephropathy. Immunofluorescence shows global, granular to globular staining for IgA limited to the mesangium. (FITC anti-

ANTI GBM DISEASE

ANTI GBM Ab AGAINST COLLAGEN ALPHA CHAIN.THESE ARE IgG CLASS[LINEAR AGAINST GBM],,TO BE SPECIFIC IgG3,IgG2,IgG1,IgG4.LIGHT STAINING FOR C3 IS SEEN IN ALMOST ALL CASES[GRANULAR OR LINEAR]

DISTAL TUBULAR MEMBRANE THAT HAVE ALPHA3 CHAIN MAY BE STAINED BY IgG.

ANTI GBM IS A CRESCENTIC GN,,THE AREA OF CRESCENT WILL NOT SHOW IgG3 STAINING FOR GBM.

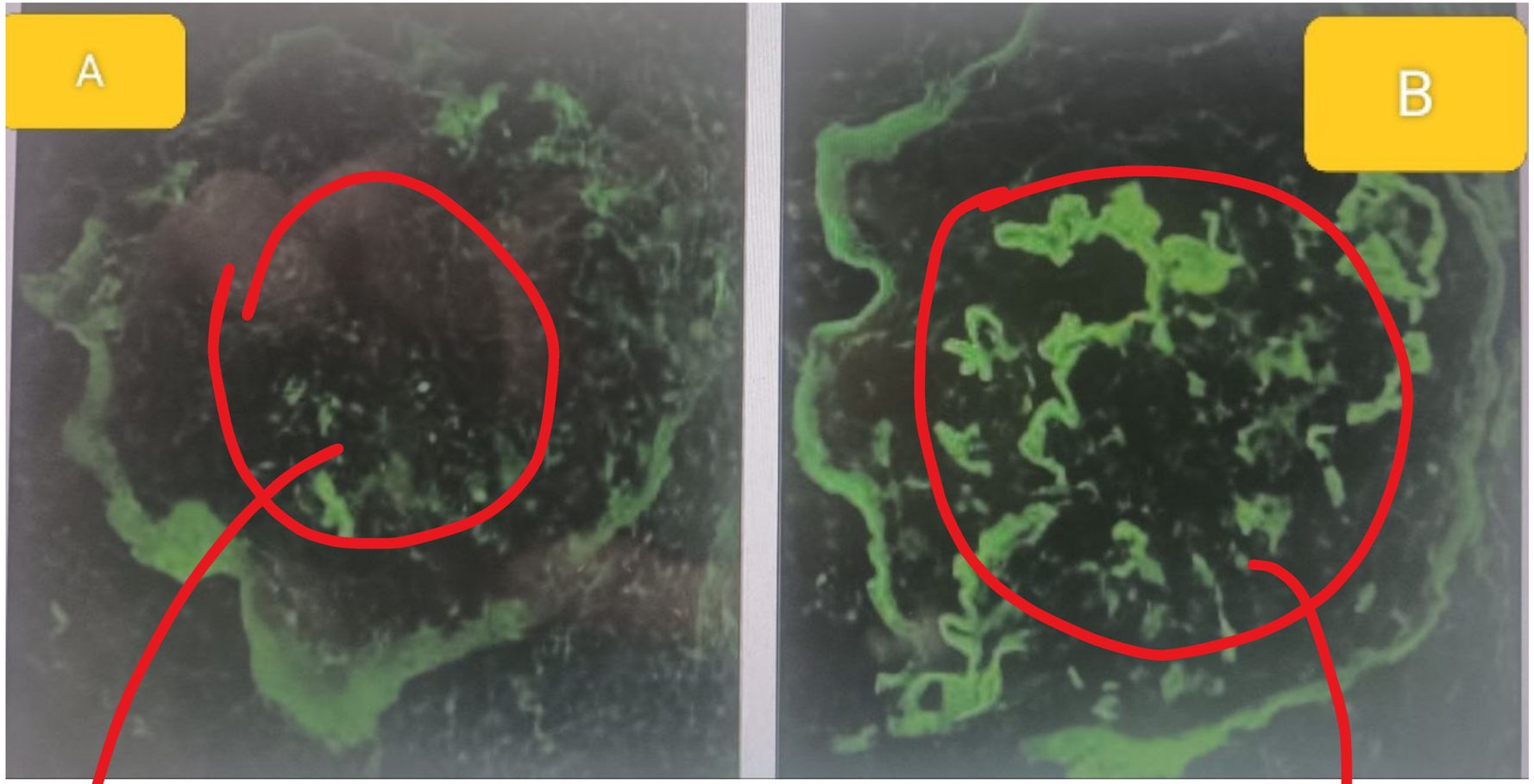

fragment of GBM is stained

More fragments of GBM stained

distal linear tubular staining for alpha3 chains

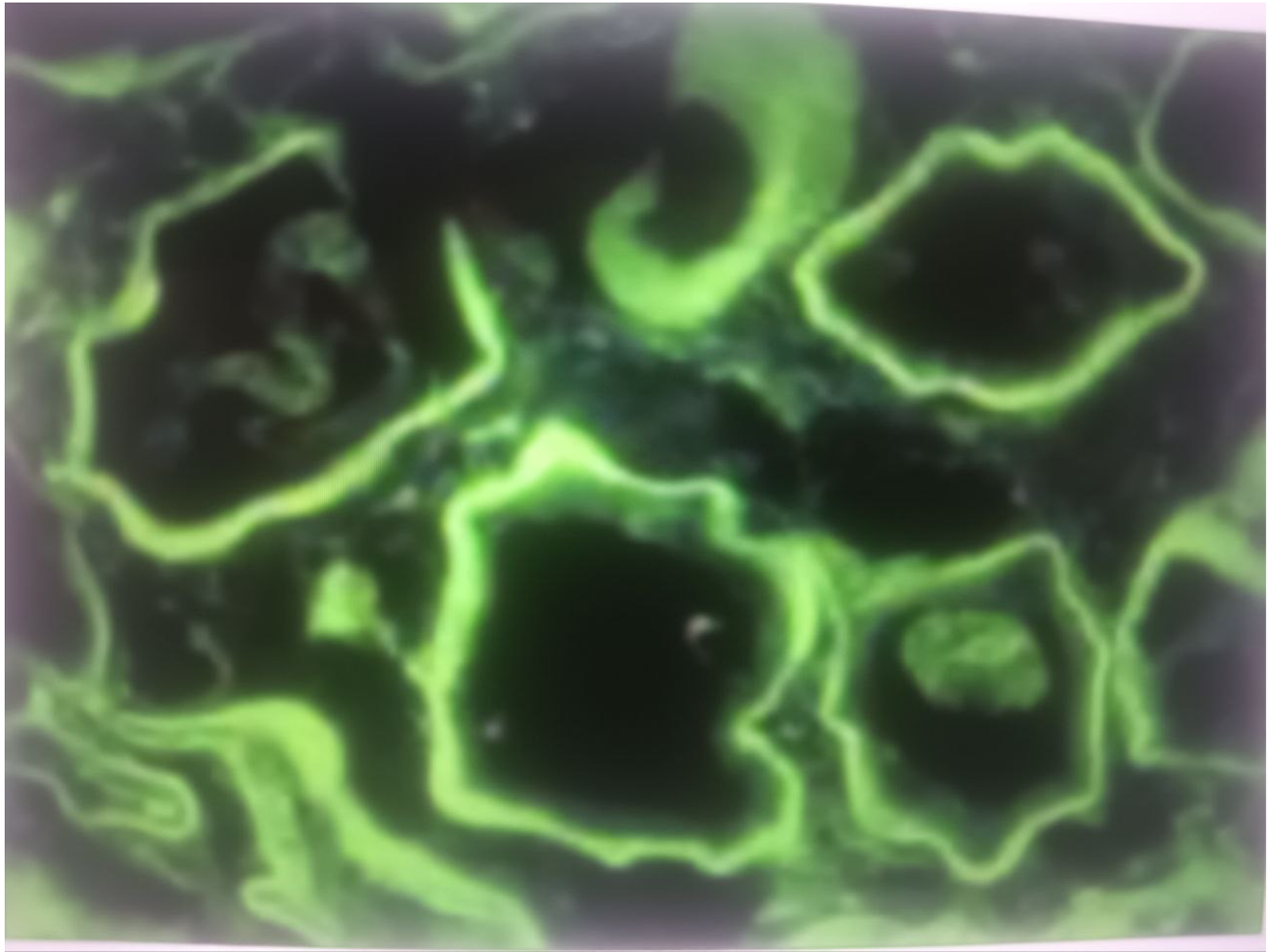

That's All
For IF



A 62-year-old male smoker presents to the renal clinic for review. He has had increasingly severe peripheral oedema over the past 4 months. His GP has checked a 24-h urinary protein excretion and found it to be 5 g/24 h. On examination his blood pressure (BP) is 145/82 mmHg, and his pulse is 80/min and regular. There are coarse crackles consistent with chronic obstructive pulmonary disease on auscultation of the chest.

Investigations:

Hb	12.4 g/dl
WCC	8.1×10^9/l
PLT	203×10^9/l
Na^+	138 mmol/l
K^+	4.9 mmol/l
Creatinine	133 μmol/l
Albumin	23 g/l

Physical examination findings as follows

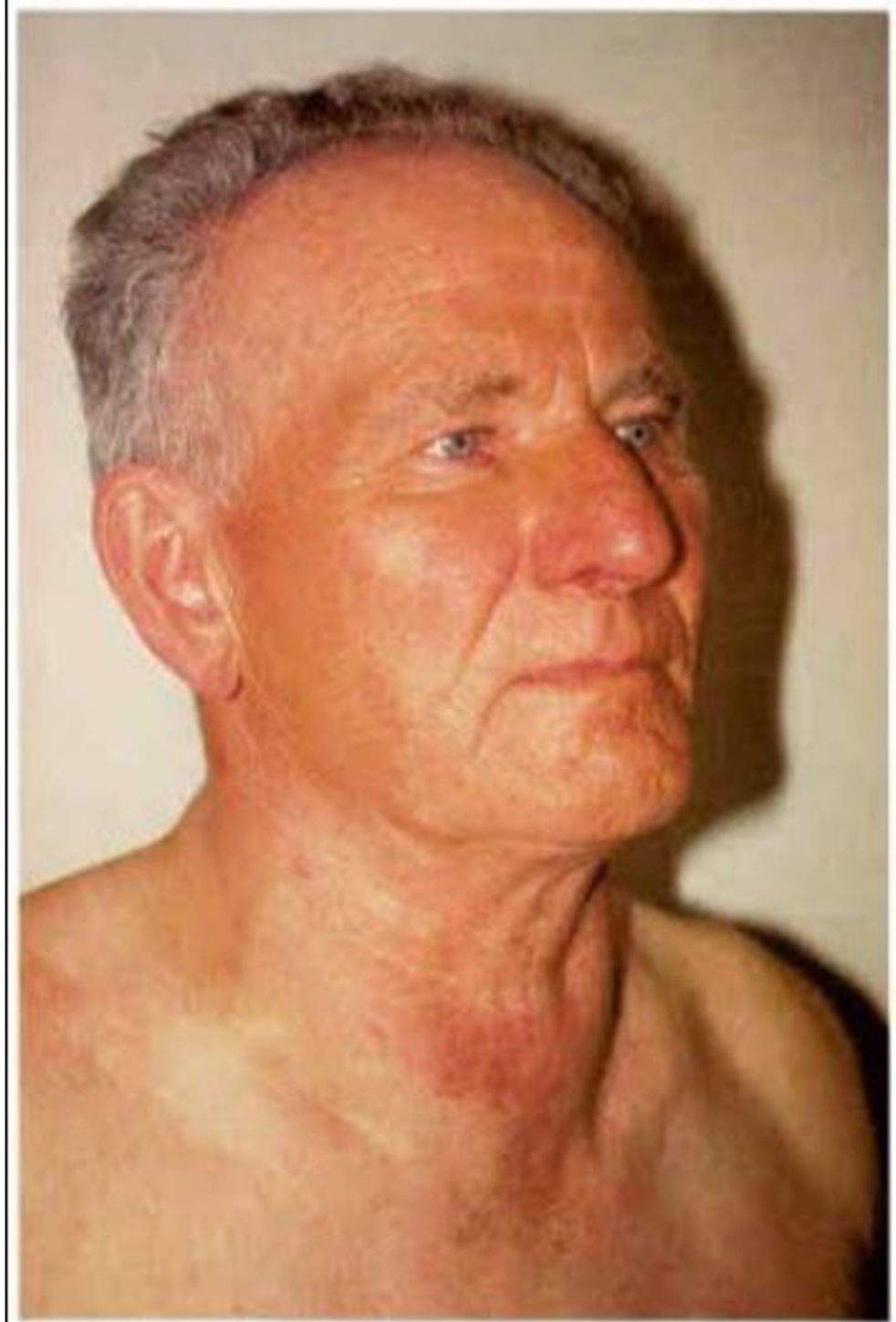

Cxr and CT are given

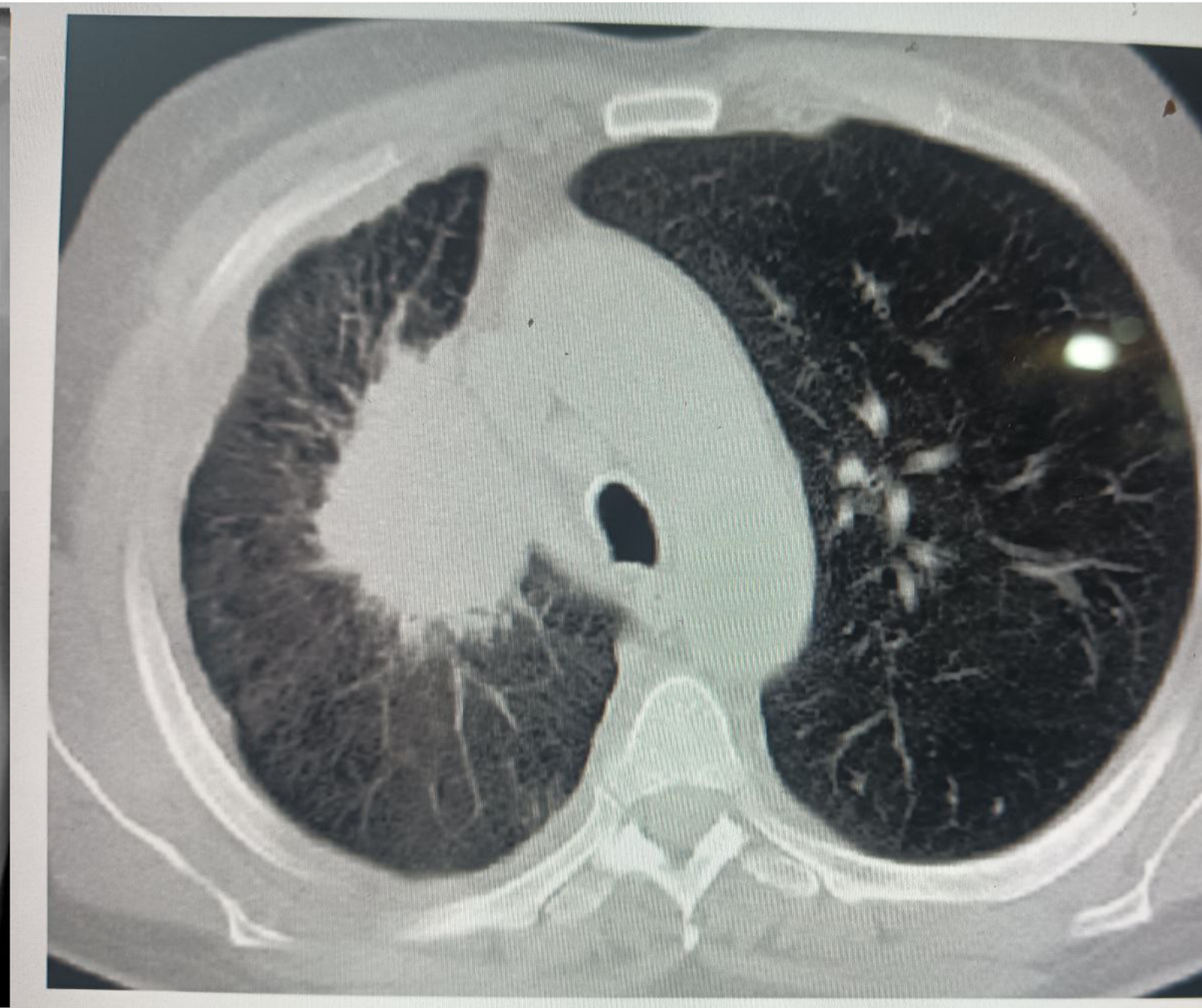

A]IgA NEPHROPATHY

B]MCD

C]MEMBRANOUS NEPHROPATHY

D]MPGN

E]PSGN

ANSWER

PSGN IS WRONG AS NO H/O SORE THROAT.

IgA NEPHROPATHY SHOULD HAVE HISTORY OF INFECTION.

PtOSIS
MIOSIS → Horner Syndrome

THIS IS PEMBERTON MANEUVER THAT SIGNIFIES SVC COMPRESSION.

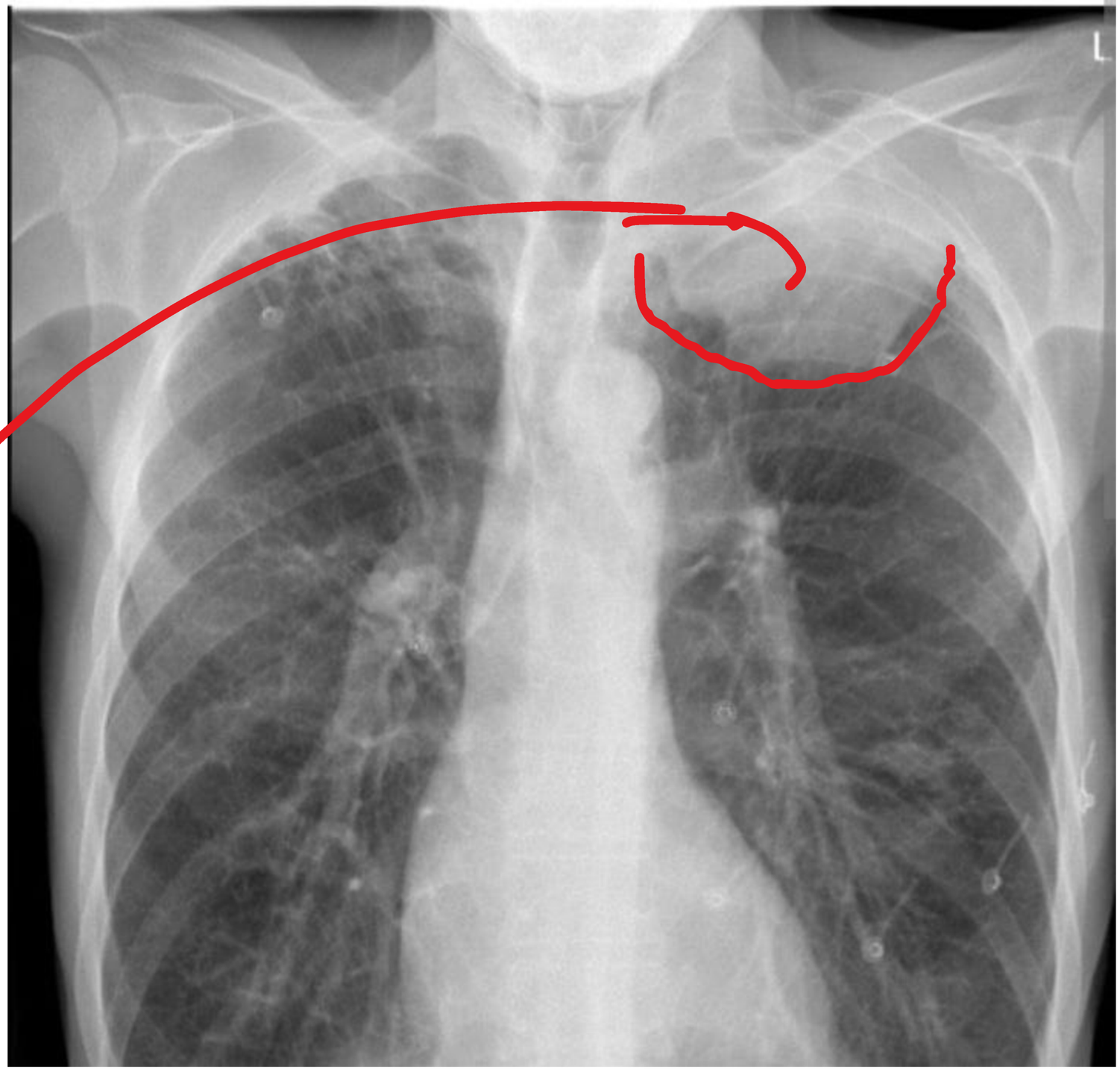
L
Solitary Nodule

BIOPSY OF THE NODULE

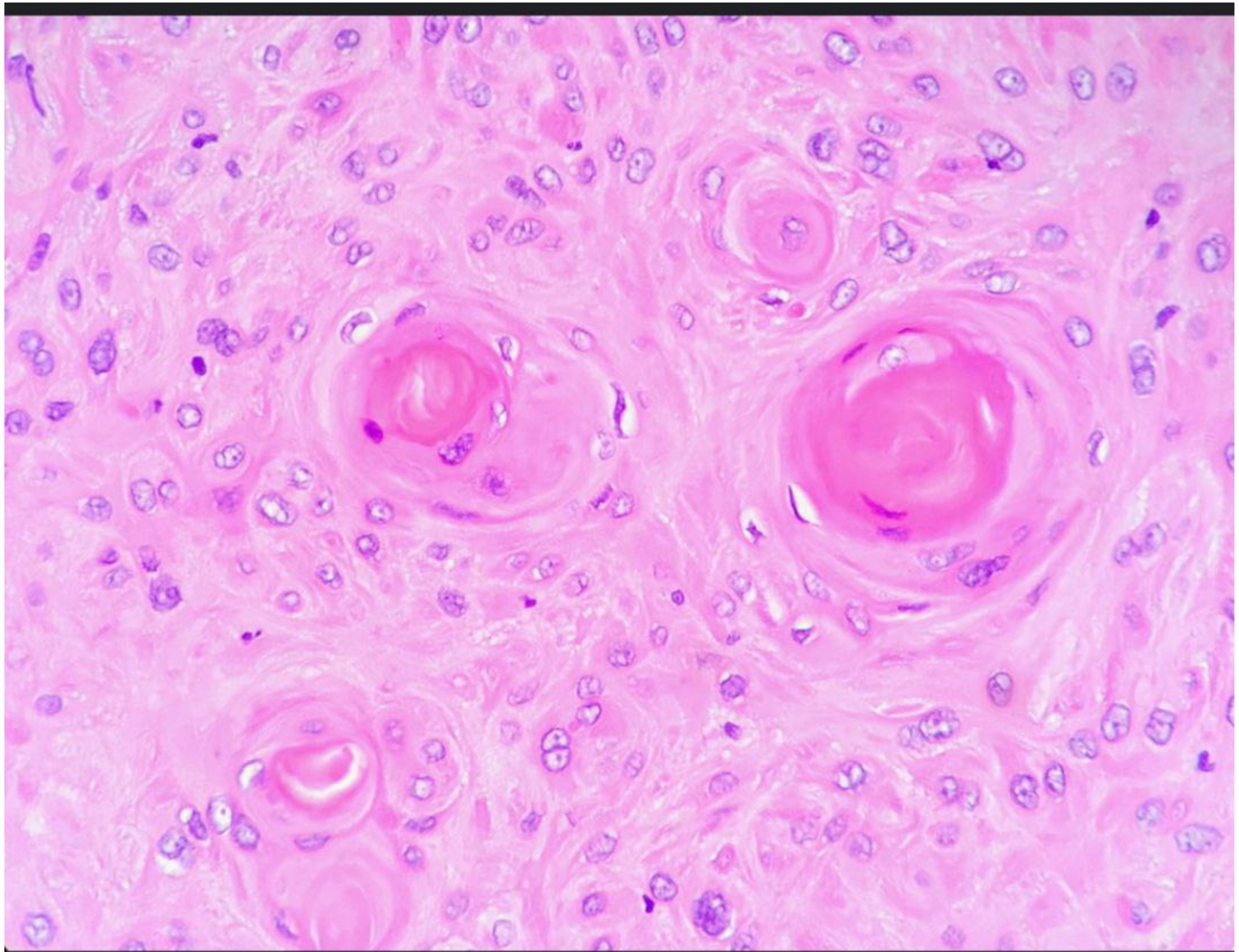

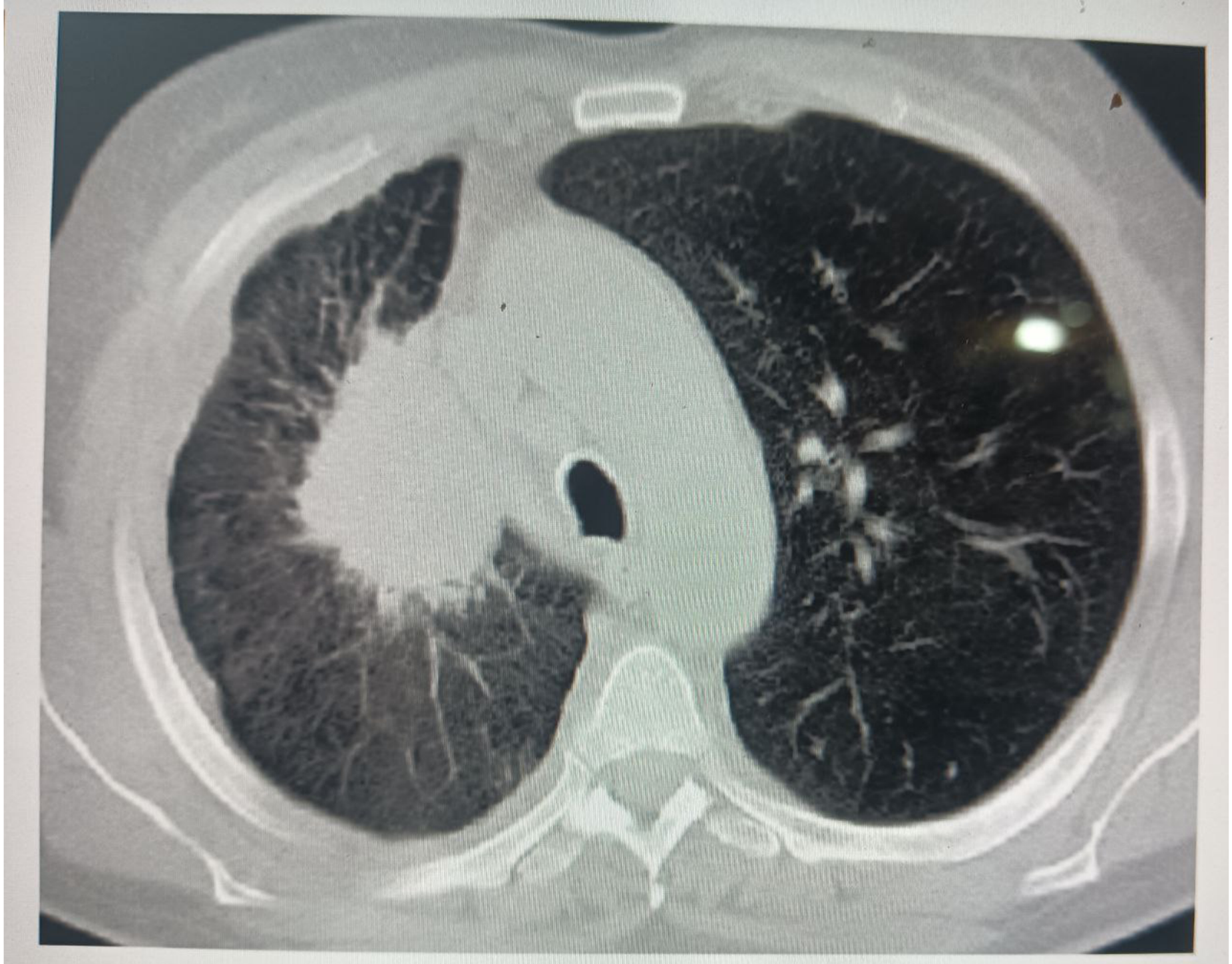

BIOPSY SHOWS KERATIN PEARLS ,,,SO THE MASS IS PROBABLY A SCC LUNG ,,A PANCOAST TUMOR THAT IS COMPRESSING THE SYMPATHETIC CHAIN CAUSING PTOSIS AND MIOSIS,,WHILE POSITIVE PEMBERTON MANEUVER IS DUE TO SVC COMPRESSION,,BY TUMOR. CT IS ALSO SHOWING TUMOR.

TABLE 18.1 Secondary Causes of Minimal Change Disease

Causes	Examples
Drugs	NSAIDs, interferon-α, lithium (rare: usually causes chronic interstitial nephritis), tamoxifen, antimicrobials (ampicillin, rifampicin, cefixime), gold (rare: usually causes membranous nephropathy), mercury in skin-lightening products
Allergy	Pollen, house dust, insect stings, poison oak
Hematologic conditions	Hodgkin disease, non-Hodgkin lymphoma, leukemia, hemophagocytic syndrome, myelodysplastic syndrome
Solid organ tumors	Most commonly lung, colorectal, renal cell carcinoma, thymoma (rare: pancreatic, breast, bladder, ovarian)
Other	Immunizations

NSAIDs, Nonsteroidal antiinflammatory drugs.

CHECK MY NOTES SECTION IN MEMBRANOUS NEPHROPATHY WHERE ONE OF THE CAUSE IS LUNG CA,,LUNG CA CAN ALSO CAUSE MCD AS SHOWN IN THE TABLE. BUT ITS MORE COMMONLY ASSOCIATED WITH MEMBRANOUS NEPHROPATHY.SO ANSWER IS OPTION C

A 35 year old man presents with renal stones. He has intermittent polydipsia and polyuria. His father also had issues of renal stones. Both of them were advised to drink lots of fluid. The man also has problem of indigestion for which he takes antacids. Blood pressure is 125/82 with pulse 75 bpm regular.

Hb:-NORMAL
WBC NORMAL
Plt normal
Na,K NORMAL
S.CREAT HIGH
S.Ca HIGH
PTH JUST ABOVE NORNAL RANGE
24 hr URINARY CALCIUM EXCRETION LOW

Answer

our patient has strong family history of stones and has indigestion with renal insufficiency[high creatinine] so metabolic stone evaluation has to be done

BOX 52-1 Indications for a Metabolic Stone Evaluation

- Recurrent stone formers
- Strong family history of stones
- Intestinal disease (particularly chronic diarrhea)
- Pathologic skeletal fractures
- Osteoporosis
- History of urinary tract infection with calculi
- Personal history of gout
- Infirm health (unable to tolerate repeat stone episodes)
- Solitary kidney
- Anatomic abnormalities
- Renal insufficiency
- Stones composed of cystine, uric acid, struvite

This is the metabolic stone evaluation i talked about in the previous slide,,compare it with the parameters given in the question

BOX 52-2 Abbreviated Evaluation of Single-Stone Formers

- History
  - Underlying predisposing conditions (as per Box 52-1)
  - Medications (calcium, vitamin C, vitamin D, acetazolamide, steroids)
  - Dietary excesses, inadequate fluid intake, excessive fluid loss
- Multichannel blood screen
  - Basic metabolic panel (sodium, potassium, chloride, carbon dioxide, blood urea nitrogen, creatinine)
  - Calcium
  - Intact parathyroid hormone
  - Uric acid
- Urine
  - Urinalysis
    - pH > 7.5: infection lithiasis
    - pH < 5.5: uric acid lithiasis
    - Sediment for crystalluria
  - Urine culture
    - Urea-splitting organisms: suggestive of infection lithiasis
  - Qualitative cystine
- Radiography
  - Radiopaque stones: calcium oxalate, calcium phosphate, magnesium ammonium phosphate (struvite), cystine.
  - Radiolucent stones: uric acid, xanthine, triamterene
  - Intravenous pyelogram: radiolucent stones, anatomic abnormalities
- Stone analysis

as u may have observed that the question is revolving around hypercalcemia,,,i will briefly explain about hypercalcemia whatever is needed to solve this question

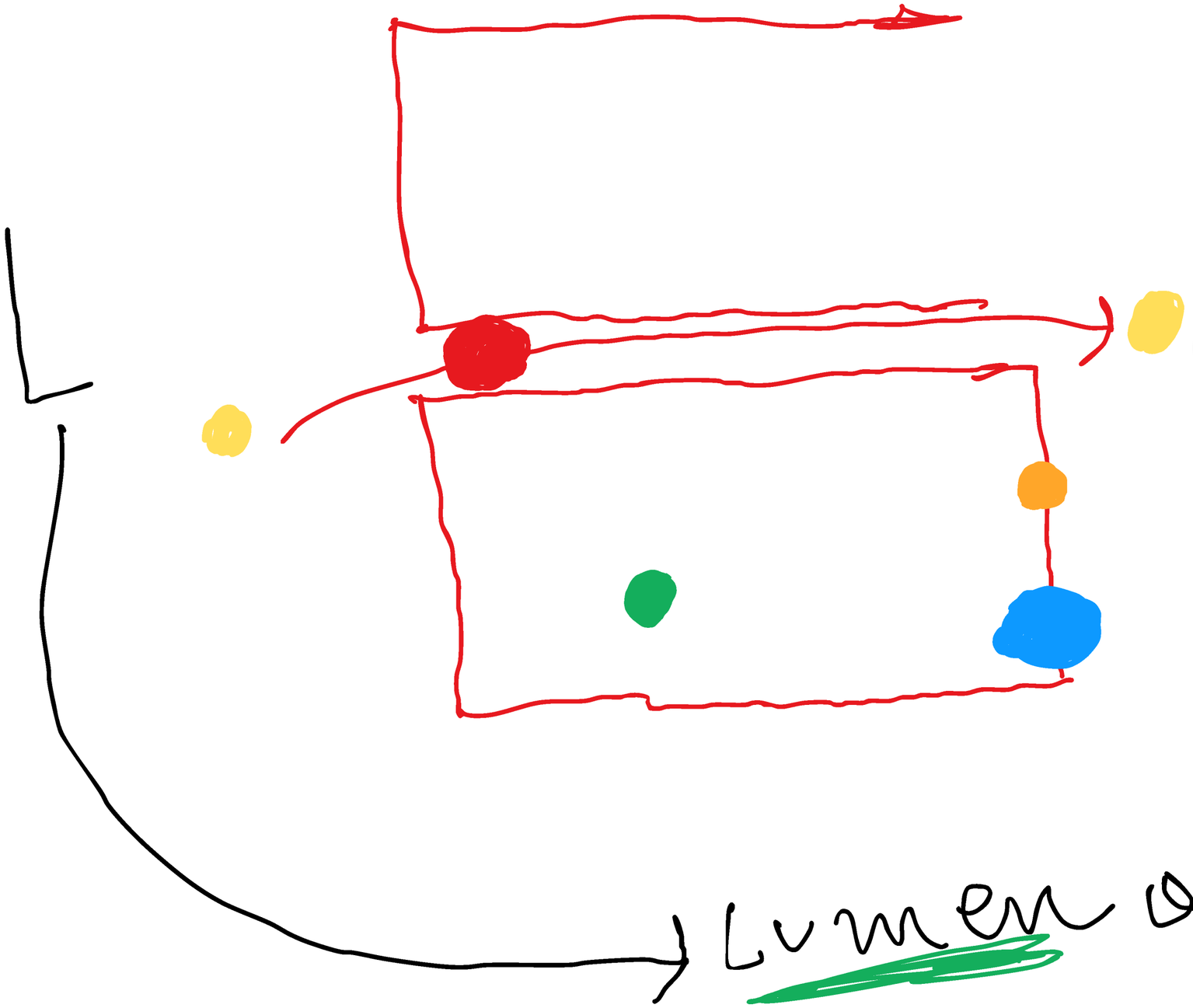

Sky blue =CasR

RED CLAUDIN 16,19

ORANGE PTHR

GREEN CLAUDIN 14

YELLOW CALCIUM

1]CLAUDIN 16,19 INCREASE REABSORBTION OF CALCIUM FROM LUMEN OF ASCENDING LIMB.

2]CasR IS CALCIUM SENSING RECEPTOR.WHEN CALCIUM BINDS TO IT,,CasR GETS ACTIVATED AND IT IN TURN ACTIVATED CLAUDIN 14 WHICH INHIBITS CLAUDIN16,19,,SO CALCIUM REABSORPTION DECREASES

3]PTH RECEPTOR WHEN STIMULATED BY PTH,CLAUDIN14 INHIBITED SO Ca reabsorption increases.

THIS WAS ALL ABOUT ASCENDING LIMB,,,LETS TALK ABOUT Ca REABSORPTION IN DCT

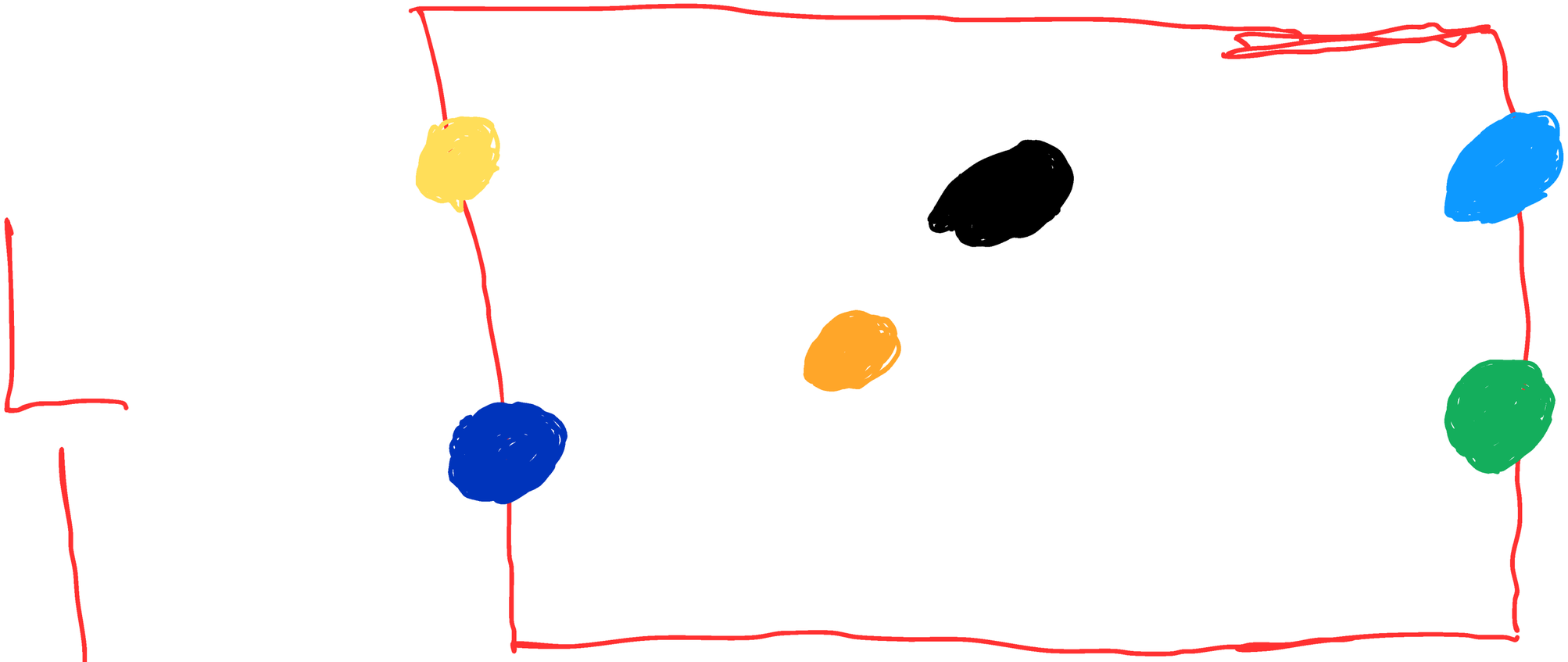

Lumen of DCT

YELLOW=TRPV6

DARK BLUE=TRPV5

ORANGE=CALBINDIN

BLACK=D28K

SKY BLUE=NaCXI

GREEN=PMCA

TRPV5,6 PROMOTE CALCIUM REABSORPTION AT LUMEN SIDE.REABSORPTED CALCIUM BINDS D28K AND CALBINDIN WITHIN THE CELL AND IS TRANSPORTED TO THE BASOLATERAL MEMBRANE.AT THE BASOLATERAL MEMBRANE NACX1,PMCA TRANSPORT CALCIUM OUT OF THE CELL ACROSS THE BASOLATERAL MEMBRANE.

ALL OF THESE TRANSPORTERS CAN BE UPREGULATED BY PTH,CALCITRIOL[VITD]

CAUSES OF HYPERCALCEMIA

1]PRIMARY HYPERPARATHYROIDISM[ADENOMA,,MEN,,MEON]

2]TERTIARY HYPERPARATHYROIDISM:-IN CKD Pts VITD ACTIVATION BY 1ALPHAHYDROXYLASE IN KIDNEY IS NOT POSSIBLE,,SO THERE WILL BE HYPOCALCEMIA INITIALLY,,THIS WILL CAUSE PARATHYROID HYPERPLASIA,,,OVER LONG RUN,,THERE WILL BE PROGRESSION TO PTH ADENOMA. LARGE AMOUNT OF PTH WILL BE SECRETED WHICH WILL RESULT ULTIMATELY IN HYPERCALCEMIA.

3]FAMILIAL HYPERCALCEMIC HYPOCALCIURIA[FHH]
SEE THE DIAGRAM IN PREVIOUS SLIDE OF ASCENDING TUBULE.IN THIS DISORDER THERE IS LOSS OF FUNCTION MUTATION IN CasR. SO CasR FUNCTION IS LOST SO CLAUDIN 14 WILL BE INHIBITED ,,SO CLAUDIN 16,19 WILL BE UPREGULATED SO CALCIUM REABSORBTION INCREASES.[THIS CAUSES HYPOCALCIURIA]MOREOVER CasR IS ALSO PRESENT ON CHIEF CELLS[PTH SECRETING CELLS] OF PARATHYROID GLAND.SO PTH WILL BE HIGH.THIS IS A AUTOSOMAL DOMINANT DISORDER

4]LITHIUM

5]INHIBITING ANTIBODIES AGAINST CasR.THIS CONDITION IS ASSOCIATED WITH CELIAC DISEASE,HASHIMOTO THYROIDITIS.THIS CONDITION IS FUNCTIONALLY SIMILAR TO FHH,, SO THERE WILL BE HYPERCALCEMIA WITH HYPOCALCIURIA.

CONDITIONS WITH HYPOCALCIURIA AND HYPERCALCEMIA ARE FHH,,ANTIBODY AGAINST CasR,,THIAZIDES,,GITELMAN SYNDROME.

ANSWER OF OUR QUESTION

ONE OF THE DIFFERENTIAL DIAGNOSIS CAN BE PARATHYROID ADENOMA.WHAT REMAINS IN DIFFERENTIAL OF HYPERCALCEMIA AND HYPOCALCIURIA IS FHH,ANTIBODY AGAINST CasR,,THIAZIDE,,GITELMAN.

SINCE THERE IS A FAMILY HISTORY THE ASNWER IS FHH[ITS A AUTOSOMAL DOMINANT DISORDER].SEE AHEAD AND READ THE UNDERLINED LINES OF THE PARAGRAPH[ITS FROM A GOOD ENDOCRINE BOOK]

In the differential diagnosis of PTH-dependent hypercalcaemia, familial hypocalciuric hypercalcaemia (FHH) is often considered. This is clearly appropriate because one does not want to mistake PHPT for FHH, particularly if parathyroid surgery is being considered for the patient. The consideration of FHH is highly relevant in young patients under the age of 30 because the disease has high penetrance by then. If there is family history of hypercalcaemia, particularly if it includes members who have had unsuccessful parathyroid surgery one should consider FHH [33]. These patients represent a very small proportion of the hyperparathyroid universe. Since most patients with PHPT are postmenopausal women whose serum calcium was known to be normal years before, the development of hypercalcaemia in their adult years virtually rules out FHH. It should be emphasized that FHH is a rare disorder and, from a statistical point of view, a postmenopausal woman who develops hypercalcaemia and elevated levels of PTH does not have FHH. A key point of distinction between PHPT and FHH, as the name implies, is that urinary excretion of calcium is very low. When compared to the creatinine clearance, the ratio of the calcium clearance:creatinine clearance (CCCR) is less than 0.01. Patients with PHPT can also have a low urinary excretion of calcium because PTH is a calcium-conserving hormone. For any amount of calcium filtered at the glomerulus, under the influence of PTH, there will be greater tubular reabsorption and less calcium excretion. A CCCR less than 0.01 can, therefore, be compatible with PHPT particularly if the patient is on a low calcium diet. If there is doubt, genetic testing for an inactivating mutation in the calcium-sensing receptor can be done readily.

Diagnosis?????

A 44-year-old male patient has returned from running his bar in Spain to the UK to seek medical advice. He is worried as he has been suffering from joint pains, is up 2 or 3 times in the night to pass urine and thirsty all the time, and is unable to maintain his erection. He has a history of hypertension for which he takes ramipril 10mg daily. On examination he looks well and is very suntanned, has a BP of 145/88 mmHg and is obese with a BMI of 32. There is seems to be a slight reduction in secondary body hair. You also notice some spider naevi on close examination of the skin.

Investigations reveal:

Hb	14.1 g/dl
WCC	4.5 $\times 10^9$/l
>PLT	245 $\times 10^9$/l
Na^+	139 mmol/l
K^+	5.0 mmol/l
Cr	145 µmol/l
ALT	90 U/l
Alk P	185 U/l

1]URINE Cu excretion

2]TRANSFERRIN SATURATION

3]CERULOPLASMIN

4]BLOOD GLUCOSE

Let’s pick up this from raised ALK P AND ALT. TABLE BY HARRISON

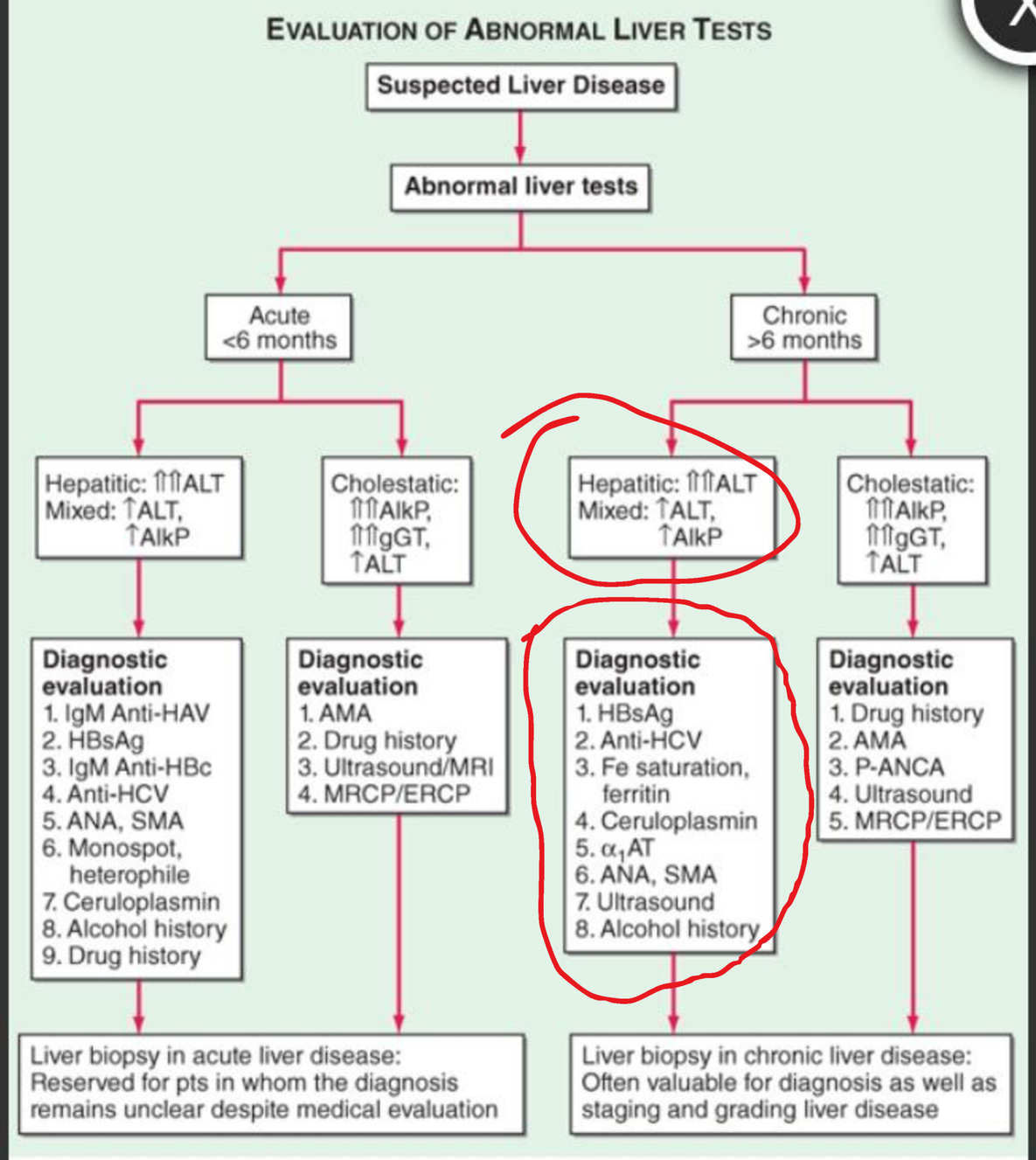

Source: J.L Jameson, A.S. Fauci, D.L. Kasper, S.L. Hauser, D.L. Longo, J. Loscalzo: Harrison's Manual of Medicine, Twentieth Edition.
Copyright © McGraw-Hill Education. All rights reserved.

cerulosplasmin is for Wilson disease but there are no neurological or ophthalmologist signs in this case.Transferrin saturation is for iron metabolism.

table from Harrison for approach to arthritis

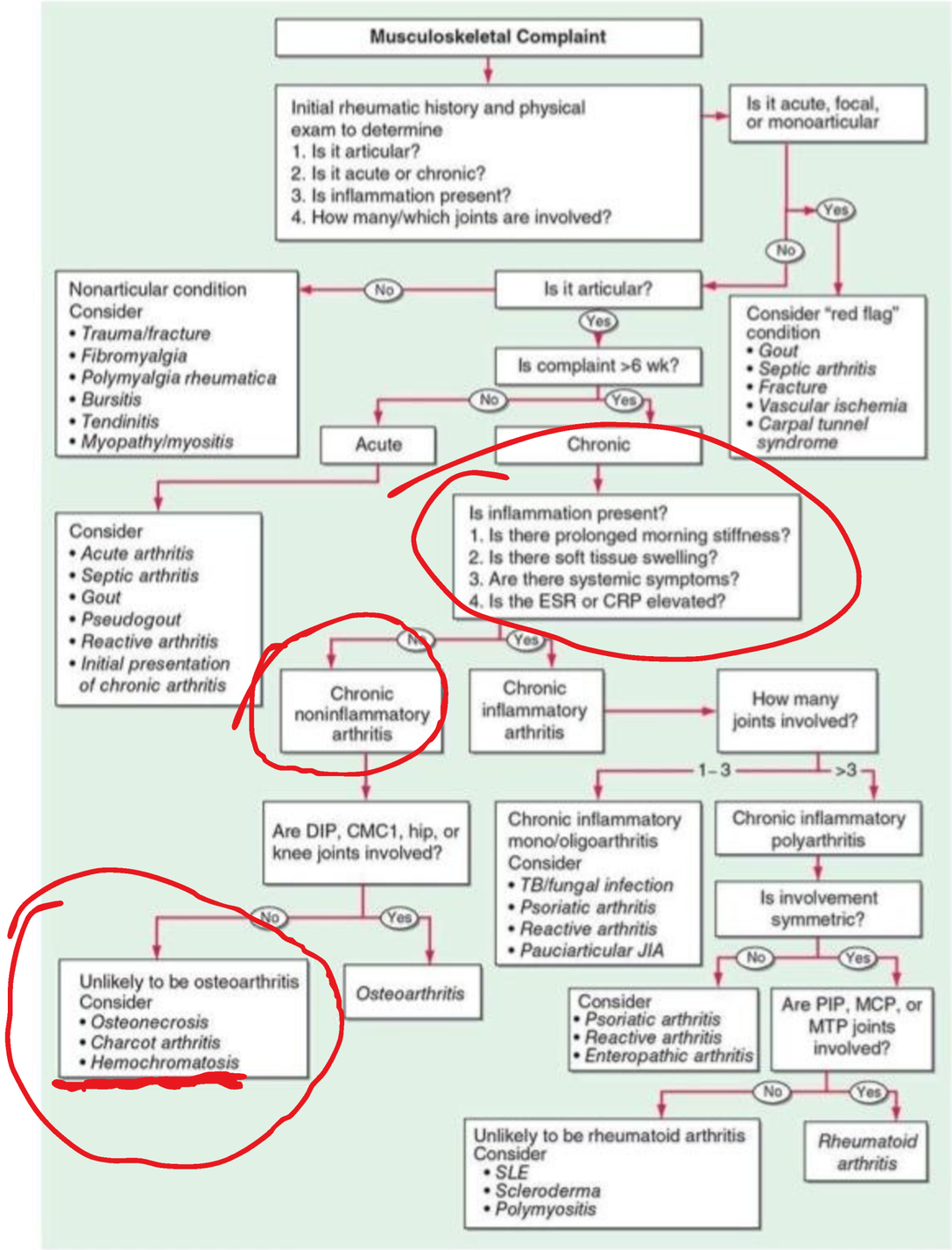
Musculoskeletal Complaint
Initial rheumatic history and physical exam to determine
1. Is it articular?
2. Is it acute or chronic?
3. Is inflammation present?
4. How many/which joints are involved?
Is it acute, focal, or monoarticular
Yes
No
Consider "red flag" condition
• Gout
• Septic arthritis
• Fracture
• Vascular ischemia
• Carpal tunnel syndrome
Is it articular?
No
Nonarticular condition
Consider
• Trauma/fracture
• Fibromyalgia
• Polymyalgia rheumatica
• Bursitis
• Tendinitis
• Myopathy/myositis
Yes
Is complaint >6 wk?
No
Yes
Acute
Chronic
Consider
• Acute arthritis
• Septic arthritis
• Gout
• Pseudogout
• Reactive arthritis
• Initial presentation of chronic arthritis
Is inflammation present?
1. Is there prolonged morning stiffness?
2. Is there soft tissue swelling?
3. Are there systemic symptoms?
4. Is the ESR or CRP elevated?
No
Yes
Chronic noninflammatory arthritis
Chronic inflammatory arthritis
How many joints involved?
1–3
>3
Are DIP, CMC1, hip, or knee joints involved?
Chronic inflammatory mono/oligoarthritis
Consider
• TB/fungal infection
• Psoriatic arthritis
• Reactive arthritis
• Pauciarticular JIA
Chronic inflammatory polyarthritis
Is involvement symmetric?
No
Yes
Consider
• Psoriatic arthritis
• Reactive arthritis
• Enteropathic arthritis
Are PIP, MCP, or MTP joints involved?
No
Yes
Unlikely to be rheumatoid arthritis
Consider
• SLE
• Scleroderma
• Polymyositis
Rheumatoid arthritis
No
Yes
Unlikely to be osteoarthritis
Consider
• Osteonecrosis
• Charcot arthritis
• Hemochromatosis
Osteoarthritis

this explains the urge to urinate at night and thirst,,both of which probably signify DM in hemochromatosis in pancreas

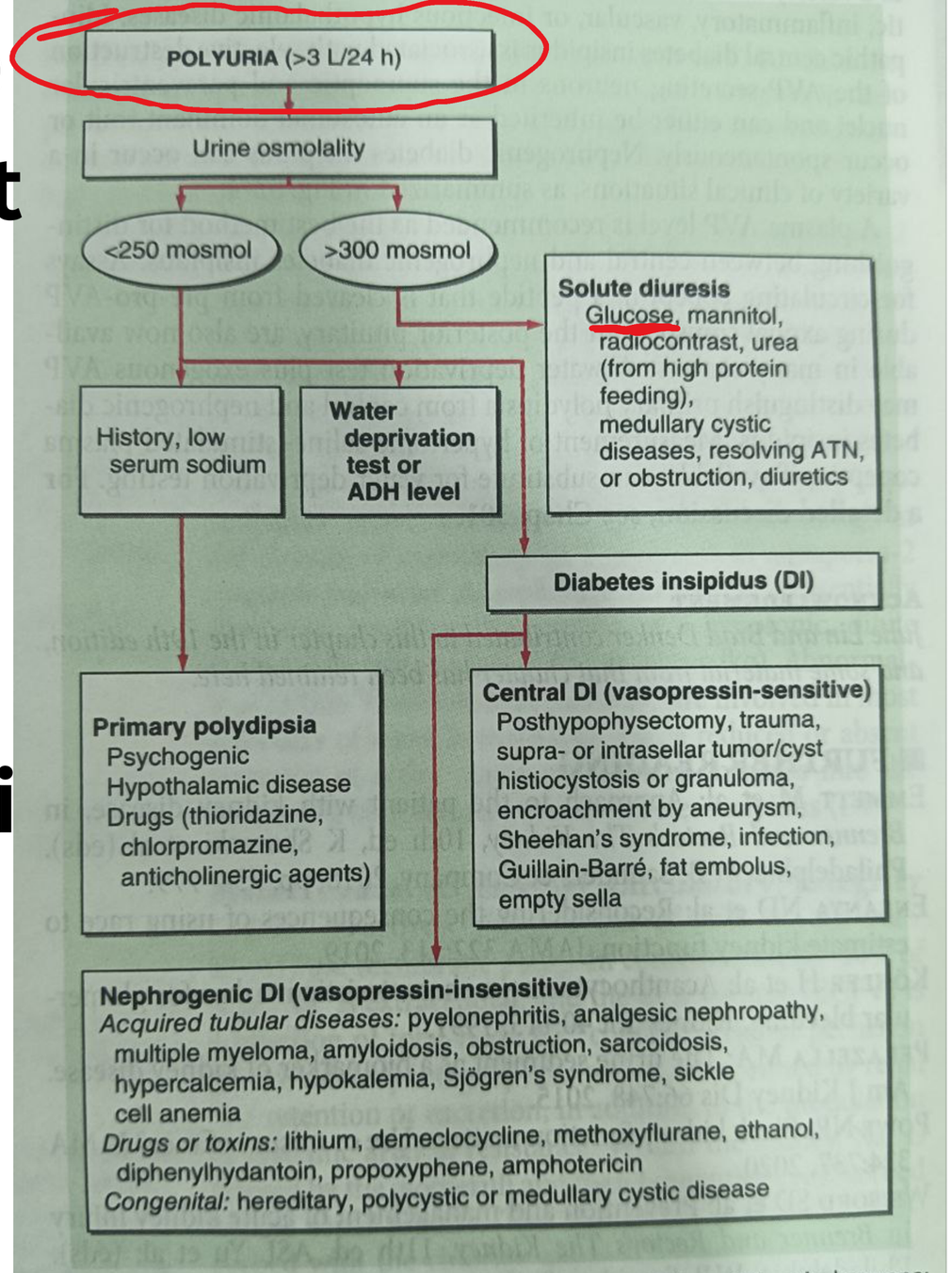

FIGURE 52-4 Approach to the patient with polyuria. ADH, antidiuretic hormone; ATN, acute tubular necrosis.

loss of secondary hair suggest some sort of defect with androgen action,,that may be due to deposition of iron in pituitary causing low GnRh.This also explains his erectile dysfunction.

liver enzymes are raised as hemochromatosis is one of the cause for cirrhosis,,which is evident in this case as spider nevi that are dilated vascular channels due to high estrogenic state in cirrhotic condition.



25 year old man has had recurrent attacks of hepatitis. He now present with muscle weakness, bone pain polyuria, polydipsia. His past medical history includes recurrent UTI. There is no family history of hepatitis. which of the following is the most common association with this condition?

A]HYPERKALEMIA
B]HYPERCALCEMIA
C]HYPOPHOSPHATEMIA
D]HIGH SERUM BICARBONATE
E]METABOLIC ALKALOSIS

EYE EXAMINATION REVEALS THE FOLLOWING

I WANT TO PICK UP THIS QUESTION FROM BONE PAIN.WITH HONESTY,,WHEN I WAS SOLVING THIS QUESTION WHAT CAME TO MY MIND BY SEEING BONE PAIN WAS OSTEOPOROSIS[BONE MINERAL METABOLISM DEFECT].

THE HALLMARK OF OSTEOPOROSIS IS LOSS OF BONE MINERAL AND PROTEIN.

MINEREAL PART IS MADE OF CALCIUM AND PHOSPHATE.

I WOULD NOW LIKW TO EXPLAIN CALCIUM METABOLISM.I HAVE ALREADY EXPLAINED HYPERCALCEMIA IN PRECEDING SLIDES,,NOW I WILL EXPLAIN HYPOCALCEMIA AND PHOSPHATE RENAL REABSORBTION.

PHOSPHATE REABSORPTION IN KIDNEY

80% REABSORPTION IN PCT

8-10% REABSORPTION IN DCT

10-12% EXCRETED.

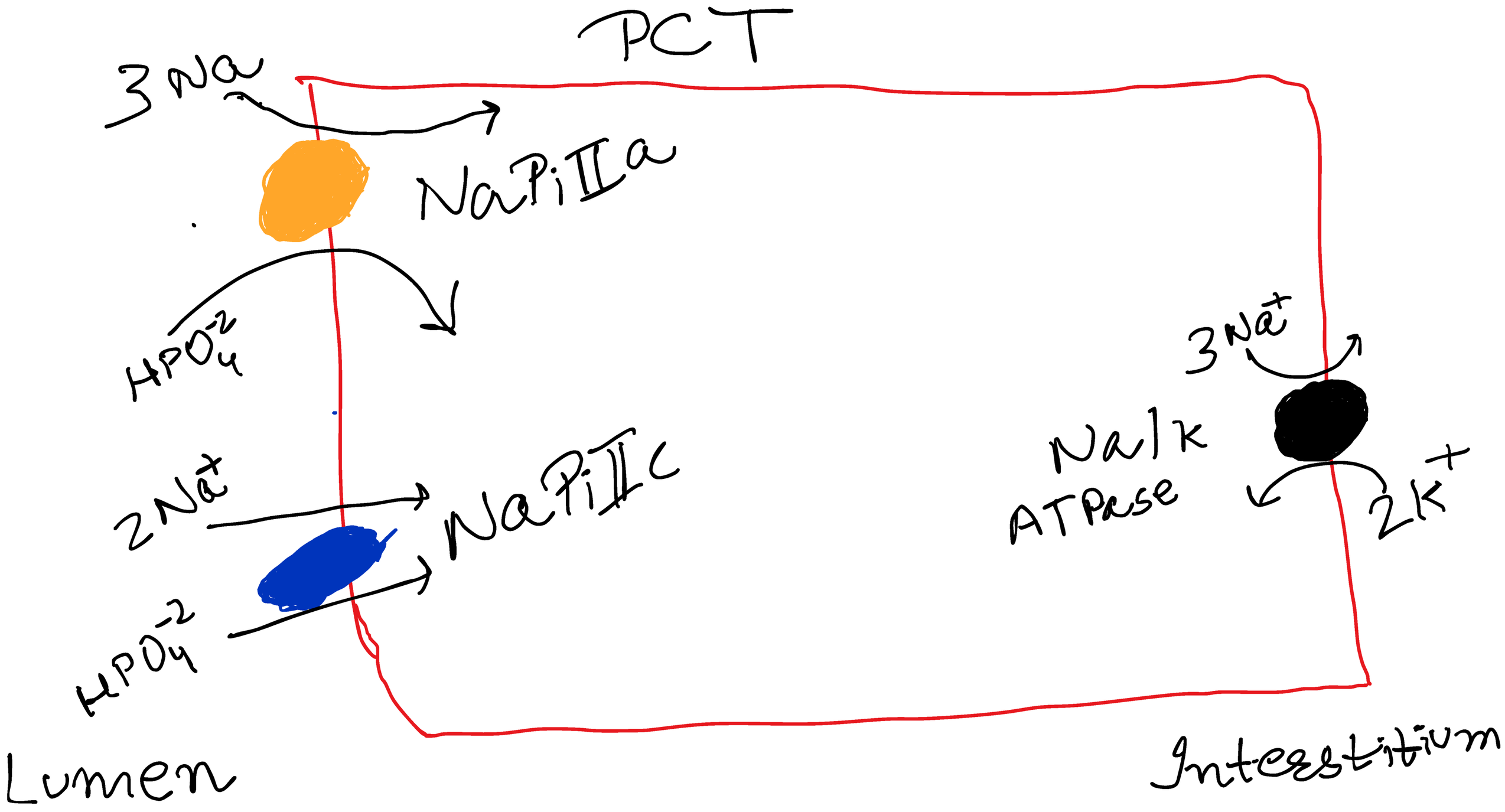
PCT
3Na
NaPiIIa
HPO_4^{-2}
$2Na^+$
NaPiIIc
HPO_4^{-2}
$3Na^+$
Na/K
ATPase
$2K^+$
Lumen
Interstitium

Na+ ions at the lumen side move from high concentration[filtrate/urine] to lower concentration[inside the pct cell].this will release energy,,this released energy will be utilized to move phosphate ions from low concentration[filtrate/urine] to higher concentration [inside the PCT cell].

PTH WORKS BY TRAPPING NAPiIIa,c INSIDE SMALL VESICLES LOCATED JUST BELOW LUMEN SIDE OF MEMBRANE /APICAL MEMBRANE.THIS EXPLAINS WHY PTH CAUSES EXCRETION OF PHOSPHATE IN URINE.

CALCITRIOL INCREASES NUMBER OF NaPiIIa,c AND IS HENCE HYPERPHOSPHATEMIC.

PTH EFFECT ON NaPiIIa,c IS DUE TO GPCR PATHWAYS[JUST MUG IT UP]

1]CAMP,PKA PATHWAY FOR RAPID EFFECT

2]IP3/DAG FOR LONG TERM EFFECT.

NOTE:-PTH ALSO INHIBITS Na/K ATPase AND Na/H EXCHANGER.

CAUSES OF HYPOCALCEMIA

AT FIRST I WILL EXPLAIN IT IN A TEXT FORM AND THEN I WILL PROVIDE A TABLE FOR SUMMARISING IT ALL.

1]CALCIUM LOW PTH LOW:-THIS IS INTERPRETED AS ,,PTH IS DECREASED THAT DECREASED THE CALCIUM LEVEL,KNOWN AS TRUE HYPOPARATHYROIDISM, OR PTH RELATED HYPOCALCEMIA.

2] CALCIUM LOW ,PTH HIGH:-

2A]CALCIUM LEVELS DECREASED THAT INCREASED THE PTH LEVELS Eg VIT D DEFECIENCY.HIGH PTH WILL ACT ON PCT[NaPiIIa,c] TO INCREASE PHOSPHATE EXCRETION IN URINE,,SO URINARY PHOSPHATE CONCENTRATION WILL BE HIGH.

2B]THERE IS RESISTENCE TO PTH RECEPTOR FOR PTH,,THAT CAUSES HYPOCALCEMIA[DUE TO RENAL LOSS],,THIS HYPOCALCEMIA IS SENSED BY CaSR ON CHIEF CELLS OF PARATHYROID GLAND WHICH INCREASES PTH SECRETION.SINCE THERE IS RESISTANCE TO PTH,, PTH WILL NOT BE ABLE TO TRAP NaPilla,c IN THE VESICLES,,SO THERE WILL BE INCREASED REABSORBTION OF PHOSPHATE ,,THIS WILL DECREASE THE URINARY CONCENTRATION OF PHOSPHATE .THIS IS KNOWN AS PSEUDOHYPOPARATHYROIDISM

BEFORE PROCEEDING FURTHER I WOULD LIKE TO EXPLAIN WHAT IS URINARY cAMP RESPONSE.

WHEN PTH INFUSION GIVEN,,PTH HAS TO BIND WITH ITS G PROTEIN COUPLED RECEPTOR[GPCR],WHICH CAN BE EITHER cAMP/PKA OR IP3/DAG PATHWAY MEDIATED.IN NORMAL CONDITION,,cAMP RESPONSE SHOULD COME AND THERE HAS TO BE INCREASE IN PHOSPHATE EXCRETION IN URINE KNOWN AS URINARY cAMP RESPONSE.

IN PSEUDOHYPOPARATHYROIDISM/PTH RESISTENCE,PTH RECEPTOR[G alpha S G PROTEIN]ON PCT CELL THAT LOWERS THE NUMBER OF NaPiIIa,c CHANNELS,,HAVE THEIR G alpha S G PROTEIN DEFECTIVE,, THIS WILL DECREASE THE URINARY CAMP RESPONSE, ONLY IN PSEUDOHYPOPARATHYROIDISM TYPE I-A,B,C. WHEREAS IN TYPE II ITS NORMAL.[U WILL GET IT MORE CLEARLY IN THE TABLE THAT I WILL PROVIDE].

ALBRIGHT HEREDITARY OSTEODYSTROPHY[AHO]

C/F:-SHORT STATURE,,ROUND FACIES,,OBESITY,,SUBCUTANEOUS OSSIFICATION,,SHORT 4TH METACARPAL.

PSEUDOHYPOPARATHYROIDISM WITH LOW URINARY CAMP RESPONSE IS TYPE I-A,B,C. AHO IS PRESENT IN TYPE I-A,C,,ABSENT IN TYP I-B.

"Knuckle-Dimple" Signs

Affected knuckles dimple when the fist is clenched causing the 'Knuckle-dimple' sign!

1 Normal

Clenched fist has all knuckles (no dimples)

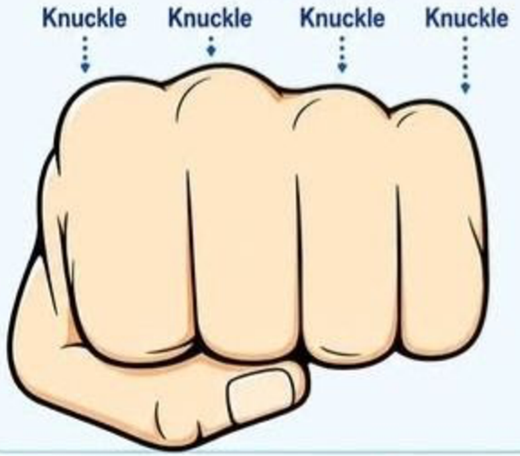

2 Down's Syndrome

- Short 3rd metacarpal bone
- "Knuckle Dimple knuckle knuckle'Sign

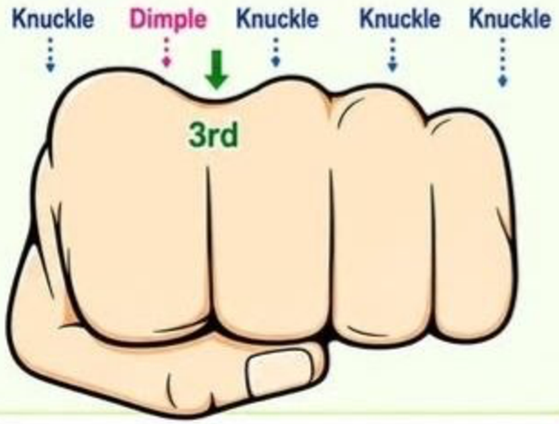

3 Turner's Syndrome

- Short 4th metacarpal bone
- "Knuckle knuckle Dimple knuckle'Sign

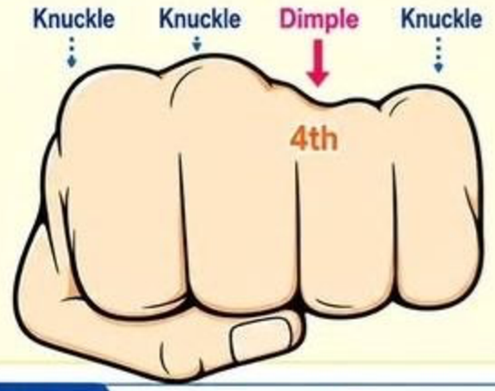

4 Pseudohypoparathyroidism type 1a

- Short 4th & 5th metacarpal bone
- "Knuckle knuckle Dimple Dimple'Sign

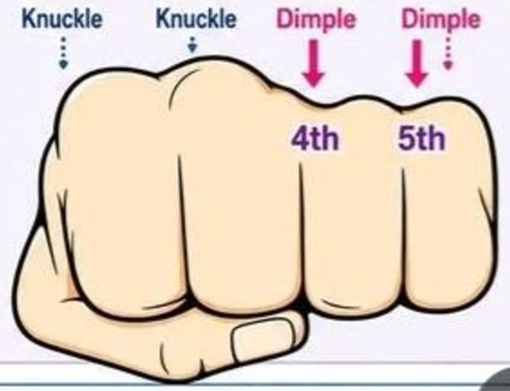

Quick Guide			
No dimples Normal	3rd Dimple at 3rd Down's Syndrome	4th Dimple at 4th Turner's Syndrome	4th 5th Dimples at 4th & 5th Pseudohypoparathyroidism type 1a

20th Notebook

PSEUDOPSEUDOHYPOPARATHYROIDISM

IT IS A CONDITION IN WHICH S.CALCIUM IS LOW,,PTH IS HIGH,,URINARY PHOSPHATE IS HIGH.THERE IS TWO DIFFERENTIALS FOR THIS CONDITIONS:-

1]PTH UNRELATED HYPOCALCEMIA
2]PSEUDOPSEUDOHYPOPARATHYROIDISM

PSEUDOPSEUDOHYPOPARATHYROIDISM IS ASSOCIATED WITH AHO.

CONDITIONS WHERE THERE IS LOW CALCIUM AND HIGH PHOSPHATE IN BLOOD

1]TRUE HYPOPARATHYROIDISM

2]PSEUDOHYPERPARATHYROIDISM

3]HYPOMAGNESEMIA[IMPAIRS PTH SECRETION]

4]AKI,CKD

5]CELL BREAKDOWN HEMOLYSIS RHABDOMYOLYSIS TLS

Ca^{++} ↓

PO_4^{-3} ↑

↓ True hypoparathy.

↓ Pseudohypoparathy.

⇓

PTH levels

↓ ↑ ⇓ Pseudohypoparathyr.

↓ True hypo Parathyr.

Causes of hypocalcemia

Ca^{++} ↓

- PTH ↓ → PTH-related hypocalcemia
  - e.g. Tetany hypopara
- PTH ↑
  - PTH unrelated hypocalcemia
  - Pseudo hypoparathy
    - ⇓ Urine PO_4^{-3}
      - ↑ ⇒ PTH unrelated hypocalcemia
      - ⇒ Pseudo pseudo hypoparathyroidism (AHO = +ve)
      - ↓ Pseudohypo para. Type I-A, B, C; Type II
        - ⇓ Urinary cAMP Response
          - ↓ Type I-A, B, C
            - ⇓ AHO
              - +ve: A, C
              - −ve: B
          - (N) Type II

SEE THE CAUSES OF HYPERCALCEMIA IN THE PRECEDING SLIDES IF U REMEMBER THAT QUESTION.NONE OF THEM FITS WITH HISTORY OF HEPATITIS.LETS COME TO HYPOCALCEMIA CAUSES.WILSON DISEASE AND HEMOCHROMATOSIS FITS WITH RECURRENT HEPATITIS.THE EYE EXAMINATION FINDING IS CONSISTENT WITH WILSON DISEASE.

CAUSES OF LOW CALCIUM

Box 4.5.1 Causes of hypocalcaemia

Low parathyroid hormone levels (hypoparathyroidism)

- Parathyroid agenesis
  Isolated or part of complex developmental anomaly (e.g. DiGeorge syndrome)
- Parathyroid destruction
  Surgery*, irradiation
  Infiltration by metastases or systemic disease (e.g. amyloidosis or sarcoidosis) or by copper or iron overload (e.g. Wilson's disease, haemochromatosis, recurrent iron transfusions for thalassaemia)
  Autoimmune
  – Isolated
  – Pluriglandular Autoimmune Hypoparathyroidism
- Reduced parathyroid function
  Parathyroid hormone gene defects
  Hypomagnesaemia*
  Neonatal hypocalcaemia (may be caused by maternal hypercalcaemia)
  Autosomal dominant hypocalcaemia†

High parathyroid hormone levels (secondary hyperparathyroidism or parathyroid hormone resistance)

- Vitamin D deficiency*
  Reduced sunlight exposure*, nutritional lack*, malabsorption*, liver disease, chronic renal failure*
- Vitamin D resistance (rickets)
  Renal tubular dysfunction (Fanconi's syndrome), vitamin D receptor defects
- Drugs
  Calcium chelators (e.g. citrated blood transfusions, phosphate)
  Antiresorptives (e.g. bisphosphonates, denosumab)
  Calcimimetics (e.g. cinacalcet)
  Altered vitamin D metabolism (e.g. phenytoin, ketoconazole)
- Miscellaneous
  Acute pancreatitis
  Rhabdomyolysis
  Massive tumour lysis
  Osteoblastic metastases (e.g. from prostate)
  Toxic shock syndrome
  Hyperventilation
- Parathyroid hormone resistance
  Hypomagnesaemia, pseudohypoparathyroidism

* Most common causes
† Plasma parathyroid hormone concentrations may be normal

LETS SEE EXTRAHEPATIC MENIFESTATION OF WILSON DISEASE.

Involvement of Other Systems

Wilson disease can be accompanied by various extrahepatic disorders apart from neurologic disease. Self-limited episodes of hemolytic anemia can result from the sudden release of copper into the blood. Renal disease, mainly Fanconi syndrome, may be prominent. Findings include microscopic hematuria, aminoaciduria, phosphaturia, and defective acidification of the urine. Nephrolithiasis has also been reported. Arthritis, mainly affecting the large joints, may occur as a result of synovial copper accumulation. Other musculoskeletal problems include osteoporosis and osteochondritis dissecans. A so-called osseomuscular presentation has been reported mainly in India. Vitamin D-resistant rickets may develop as a result of the renal damage. Copper deposition in skeletal muscle can cause rhabdomyolysis. Copper deposition in the heart can lead to cardiomyopathy or cardiac arrhythmias. Sudden death in Wilson disease has been attributed to cardiac involvement but is rare. Endocrine disorders can occur. Hypoparathyroidism has been attributed to copper deposition. Amenorrhea and testicular problems appear to result from Wilson disease itself, not from cirrhosis. Infertility or repeated spontaneous abortion may signal Wilson disease. Pancreatitis, possibly resulting from copper deposition in the pancreas, may also occur.

BOX 13.2 Causes of Proximal (Type 2) Renal Tubular Acidosis

Not Associated With Fanconi Syndrome
- Sporadic
- Familial

Disorder of Carbonic Anhydrase
- Drugs: acetazolamide, sulfanilamide, topiramate
- Carbonic anhydrase II deficiency

Associated With Fanconi Syndrome
- Selective (no systemic disease present)
- Sporadic

Familial
- Autosomal recessive proximal RTA with ocular abnormalities: Na^+-HCO_3^- cotransporter (NBCe1) defect
- Autosomal recessive proximal RTA with osteopetrosis and cerebral calcification: carbonic anhydrase II defect
  - Generalized (systemic disorder present)
  - Genetic disorders
    - Cystinosis
    - Wilson disease
    - Hereditary fructose intolerance
    - Lowe syndrome
    - Metachromatic leukodystrophy

Dysproteinemic States
- Myeloma kidney
- Light chain deposition disease

Hyperparathyroidism
- Primary
- Secondary

Drugs and Toxins
- Tenofovir
- Outdated tetracycline
- Ifosfamide
- Gentamicin
- Streptozocin
- Lead
- Cadmium
- Mercury

Tubulointerstitial Disease
- Posttransplantation rejection
- Balkan nephropathy
- Medullary cystic disease

Others
- Bone fibroma
- Osteopetrosis
- Paroxysmal nocturnal hemoglobinuria

IN RTA TYPE 2 THERE IS DEFECT IN PCT ,,SO THERE WILL BE LOSS OF ELECTROLYTES [POTASSIUM,PHOSPHATE],,BICARBONATE,,AMINOACIDURIA,,GLYCOSURIA. ALL THESE CAUSES POLYURIA/OSMOTIC DIURESIS. PRESENCE OF GLUCOSE IN URINE CAUSES RECURRENT UTI.

ANSWER IS HYPOPHOSPHATEMIA



58 YEAR OLD FEMALE PRESENTS TO THE EMERGENCY DEPARTMENT WITH COMPLAINTS OF SEVERE SHORTNESS OF BREATH,BILATERAL PITTING PEDAL EDEMA.ON AUSCULTATION THERE ARE NO RALES AND BREATH SOUNDS ARE ABSENT. CXR IS GIVEN AHEAD.URINE DIPSTICK SHOWS 3+ PROTEINURIA.PATIENT IS THEN SHIFTED TO THE WARD AFTER STABILISATION.RENAL BIOPSY AND IMMUNOFLOURESCENCE ARE SHOWN AHEAD.

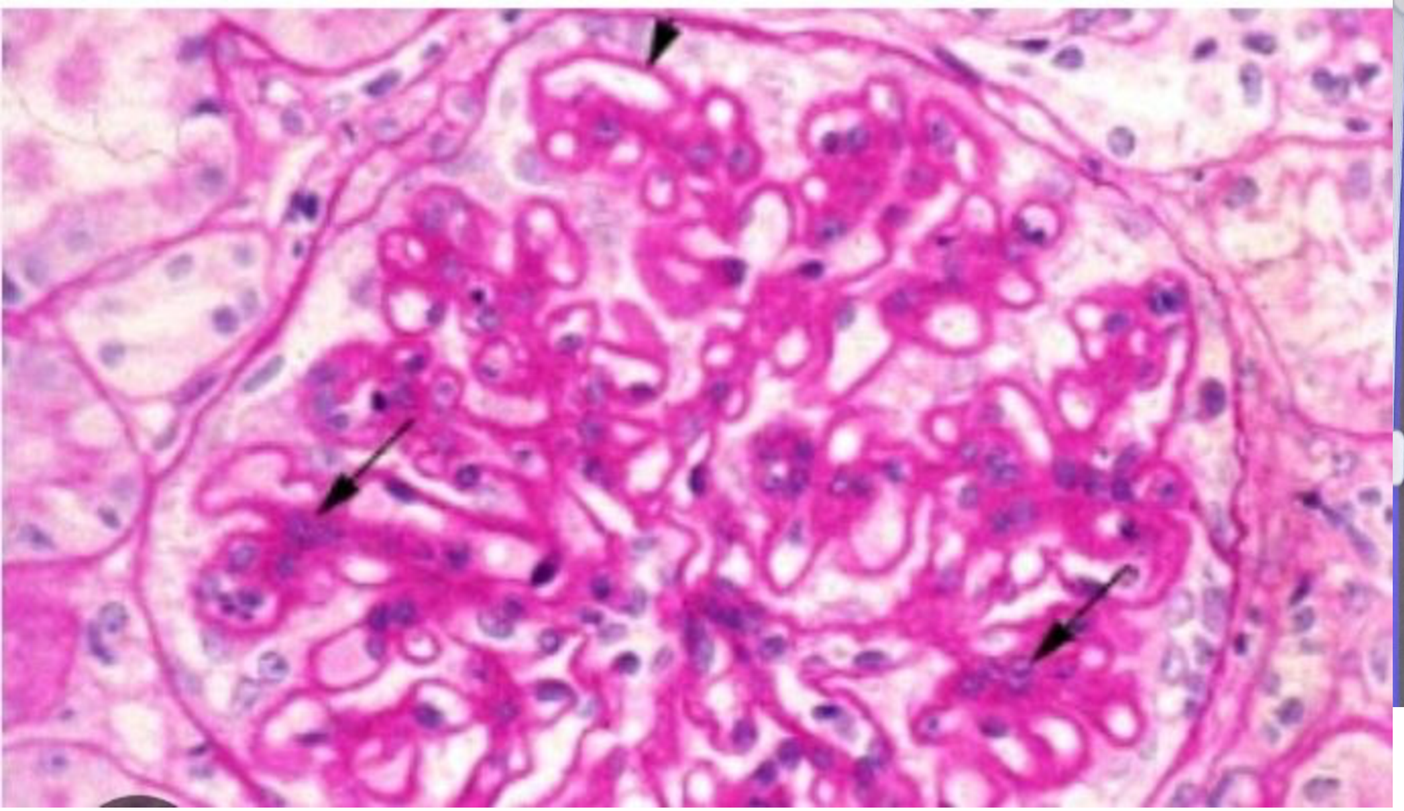

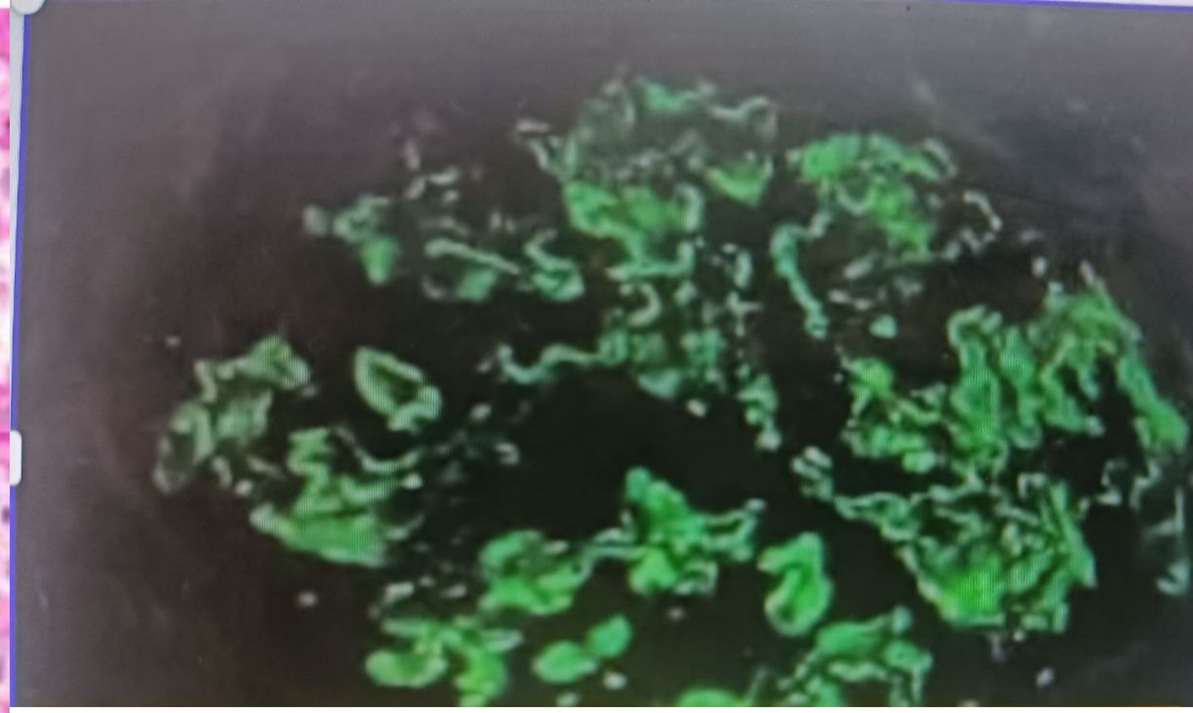

IMMUNOFLOURESCENCE IS POSITIVE FOR IgG4[STRONGLY],,WEAKLY FOR IgG1 AND IgG3.HBV IS NEGATIVE. WHAT IS THE DIAGNOSIS.

CXR SHOWS PLEURAL EFFUSION PROBABLY DUE TO NEPHROTIC SYNDROME.

BIOPSY SHOWS THICKENED GLOMERULUR CAPILLARY WALLS,,SO ITS MEMBRANOUS NEPHROPATHY.NOW GO BACK TO QUESTION NO. 9 WHERE I EXPLAINED IMMUNOFLOURESCENCE. A STRONG STAIN FOR IgG4 AND WEAK STAIN FOR IgG1 AND IgG3 SUGGESTS PRIMARY MEMBRANOUS NEPHROPATHY[ANTI PLAR2 ANTIBODY POSITIVE]

912

A 21 YEAR OLD MALE PRESENTS WITH FATIGUE,,BONE PAINS.LAB SHOWS ANEMIA LOW CALCIUM HIGH PHOSPHATE.[BLOOD SAMPLE],SERUM CREATININE HIGH. DIAGNOSIS?

A]PRIMARY HYPER PTH

B]RENAL

X-RAY OF Pt ARE SHOWN AHEAD

NOW JUST GO BACK TO QUESTION 13 WHERE I HAVE GIVEN TABLE OF APPROACH TO HYPOCALCEMIA. AFTER THAT I HAVE ALSO GIVEN OTHER CONDITION ASSOCIATED WITH LOW SERUM CALCIUM AND HIGH PHOSPHATE.

THE CAUSE THAT MATCHES THE OPTION IN THE QUESTION IS CKD, [RENAL OSTEODYSTROPHY]. THE QUETION ARISES WHY NOT OSTEOMALACIA.

OSTEOMALACIA[SOFT BONES]IS DUE TO VITAMIND DEFICIENCY IN ADULT AND IN CHILDREN DUE TO RICKETS. IN VIT D DEFICIENCY THERE WILL BE HYPOCALCEMIA WHICH WILL INCREASE PTH WHICH WILL CAUSE PHOSPHATURIA CAUSING LOW PHOSPHATE IN BLOOD.

BUT OUR PATIENT HAS HIGH SERUM PHOSPHATE SO ITS NOT OSTEOMALACIA.

IN CKD THERE IS DEFECTIVE ONE ALPHA HYDROXYLASE ENZYME SO THERE WILL BE HYPOCALCEMIA,,SO PTH WILL INCREASE,,SO THERE HAS TO HIGH PHOSPHATE EXCRETION IN URINE CAUSING LOW PHOSPHATE IN BLOOD ,,,BUT IN CKD THERE IS HIGH PHOSPHATE IN BLOOD DESPITE HIGH PTH. THIS IS BCOZ THERE ARE VERY LOW NUMBER OF FUNCTIONAL NEPHRONS IN KIDNEY OF CKD PATIENT ,,SO EVEN IF PTH IS HIGH,,PHOSPHATE WILL NOT BE EXCRETED,,CAUSING HIGH PHOSPHATE IN BLOOD.OUR Pt HAS LOW Ca AND HIGH PHOSPHATE IN BLOOD

X-RAY FINDINGS

Bredun Tumor

Subperiosteal resorption

RUGGER JERSEY SPINE

Hello

36 YEAR OLD MAN WITH CKD PRESENT WITH HYPERKALEMIA,METABOLIC ACIDOSIS,,LOW URINE CONCENTRATING ABILITY.HIS RENAL ULTRASOUND SHOWS BILATERAL SMALL KIDNEY,WHICH IS THE LIKELY DIAGNOSIS.

A]CHRONIC INTERSTITIAL NEPHRITIS

B]HYPERTENSIVE NEPHROSCLEROSIS

C]DIABETIC NEPHROPATHY

D]PCKD

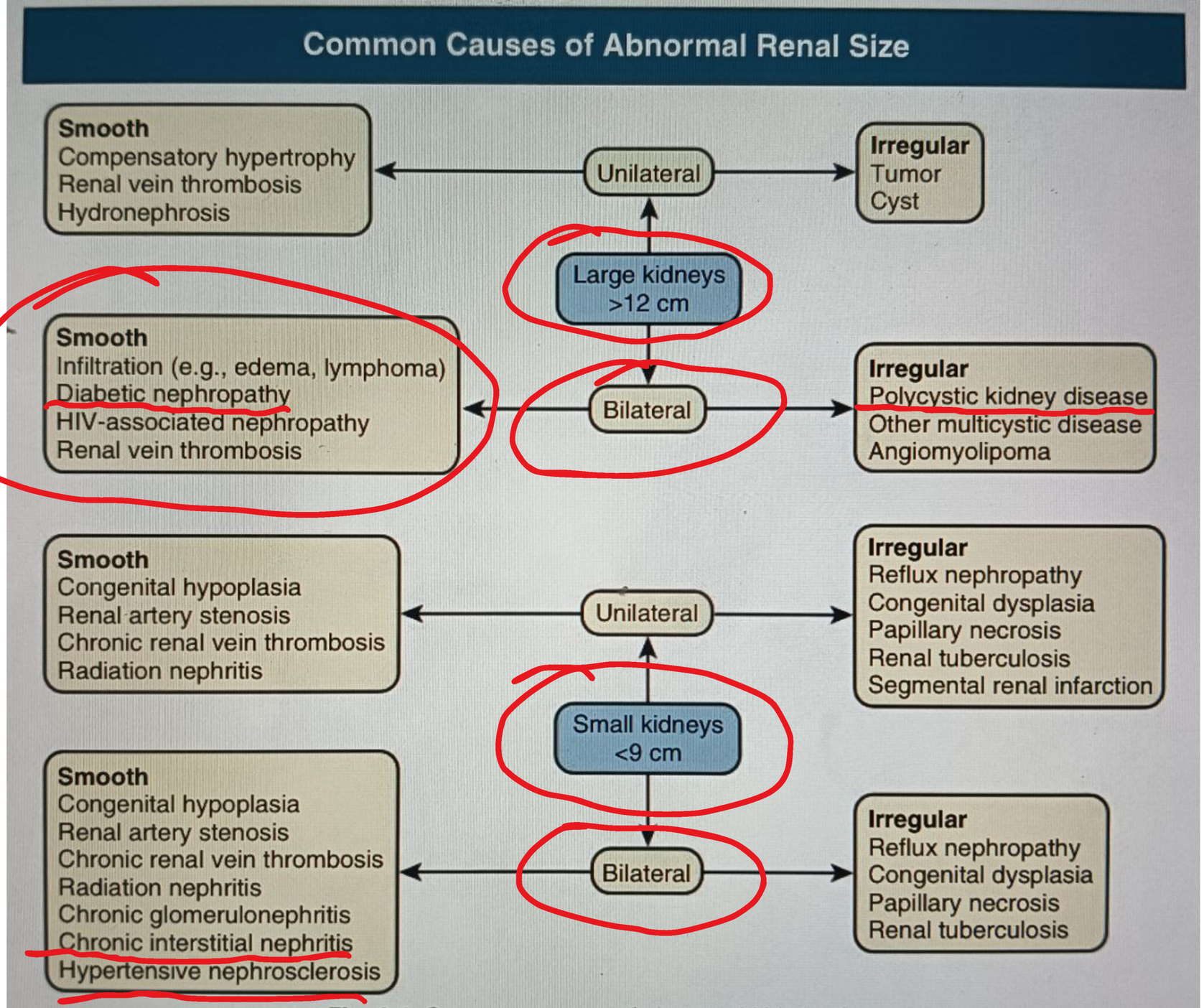

Fig. 6.1 Common causes of abnormal kidney size.

SINCE CHRONIC INTERSTITIAL NEPHRITIS NEEDS HISTORY OF DRUG USE „THE ANSWER IS HTNsive NEPHROSCLEROSIS.



WHICH FEATURES ON RENAL BIOPSY SUGGEST A SECONDARY FSGS PATTERN RELATED TO STRUCTURAL FUNCTIONAL ADAPTATION.

A]ADHESIONS TO BOWNMAN CAPSULE

B]GLOMERULOMEGALY

C]HYPERTROPHY AND HYPERPLASIA OF VISCEREL EPITHELIAL CELLS

D]DIFFUSE MESANGIAL HYPERCELLULARITY

E]COLLAPSE OF GLOMERULAR TUFT

BOX 19.1 Etiologic Classification of Focal Segmental Glomerulosclerosis

Primary
- Presumably mediated by circulating/permeability factor(s)

Genetic Causes
- (See Chapter 20)

Secondary

Virus Associated
- HIV-1 (HIV-associated nephropathy)
- SARS-CoV-2 (COVID-19 associated nephropathy)
- Parvovirus B19
- CMV
- EBV

Drug Induced
- Interferon
- Pamidronate
- Sirolimus
- Anabolic steroids

Adaptive Changes to Glomerular Hyperfiltration

Reduced Kidney Mass
- Oligomeganephronia
- Very low birth weight (correlating with low nephron endowment)
- Unilateral kidney agenesis
- Kidney dysplasia
- Reflux nephropathy
- Sequela to cortical necrosis
- Surgical kidney ablation
- Any advanced kidney disease with reduction in functioning nephrons

Initially Normal Kidney Mass
- Hypertension
- Atheroemboli or other acute vasoocclusive processes
- Obesity
- Bodybuilders
- Cyanotic congenital heart disease
- Sickle cell anemia

Uncertain Cause

Ans is option B

9/8

18. A 56-year-old man is involved in a severe motor vehicle accident. He develops ARF after admission to hospital. One of the possibilities for his ARF is posttraumatic renal vein thrombosis. Which of the following findings is most likely to suggest renal vein thrombosis?

(A) white cell casts on urinalysis
(B) heme-granular casts
(C) heavy proteinuria
(D) urine supernatant pink and tests positive for heme
(E) specific gravity >1.020

Table 31.8 Useful Clinical Features, Urinary Findings, and Confirmatory Tests in the Differential Diagnosis of Acute Kidney Injury

Cause of Acute Kidney Injury	Some Suggestive Clinical Features	Typical Urinalysis Results	Some Confirmatory Tests
Prerenal azotemia	Evidence of true volume depletion (thirst, postural or absolute hypotension and tachycardia, low jugular venous pressure, dry mucous membranes and axillae, weight loss, fluid output greater than input) or decreased effective circulatory volume (e.g., heart failure, liver failure), treatment with NSAID, diuretic, or ACE inhibitor/ARB	Hyaline casts $FE_{Na} < 1\%$ $U_{Na} < 10$ mmol/L SG > 1.018	Occasionally requires invasive hemodynamic monitoring; rapid resolution of AKI with restoration of renal perfusion
Diseases Involving Large Renal Vessels			
Renal artery thrombosis	History of atrial fibrillation or recent myocardial infarction, nausea, vomiting, flank or abdominal pain	Mild proteinuria Occasionally RBCs	Elevated LDH level with normal transaminase levels, renal arteriogram, MAG3 renal scan, MRA*
Atheroembolism	Usually age > 50 yr, recent manipulation of aorta, retinal plaques, subcutaneous nodules, palpable purpura, livedo reticularis	Often normal Eosinophiluria Rarely casts	Eosinophilia, hypocomplementemia, skin biopsy, renal biopsy
Renal vein thrombosis	Evidence of nephrotic syndrome or pulmonary embolism, flank pain	Proteinuria, hematuria	Inferior venacavogram, Doppler flow studies, MRV*
Diseases of Small Renal Vessels and Glomeruli			
Glomerulonephritis or vasculitis	Compatible clinical history (e.g., recent infection), sinusitis, lung hemorrhage, rash or skin ulcers, arthralgias, hypertension, edema	RBC or granular casts, RBCs, white blood cells, proteinuria	Low complement levels; positive antineutrophil cytoplasmic antibodies, anti–glomerular basement membrane antibodies, anti–streptolysin O antibodies, anti-DNase, cryoglobulins; renal biopsy
HUS/TTP	Compatible clinical history (e.g., recent gastrointestinal infection, cyclosporine, anovulants), pallor, ecchymoses, neurologic findings	May be normal, RBCs, mild proteinuria, rarely RBC or granular casts	Anemia, thrombocytopenia, schistocytes on peripheral blood smear, low haptoglobin level, increased LDH, renal biopsy
Malignant hypertension	Severe hypertension with headaches, cardiac failure, retinopathy, neurologic dysfunction, papilledema	May be normal, RBCs, mild proteinuria, rarely RBC casts	LVH by echocardiography or ECG, resolution of AKI with BP control
Ischemic or Nephrotoxic Acute Tubular Necrosis			

ANSWER IS HEAVY PROTEINURIA



48 year old female with a history of CKD has worsening renal function. She has been taking NSAIDS for joint pain. Her serum creatinine rises from 1.6 to 3.4 over two weeks. USG shows normal kidney size without hydronephrosis. What is the most likely mechanism of her worsening renal function?

A] bilateral renal artery stenosis
B] ATI
C] NSAIDS induced pre-renal azotemia
D] acute interstitial nephritis.

in CKD there is increased level of local angiotensin-II,,this causes efferent arteriolar constriction,,this increases intra glomerular hydrostatic pressure,,this maintains the GFR.

There is a fact that prostaglandins cause AFFERENT arteriolar dilation which also increases intra glomerular hydrostatic pressure,,and this maintains GFR. If NSAIDS are given then prostaglandin production will be blocked,,so there will be reduced AFFERENT arteriolar dilation,,this decreases GFR and causes renal deterioration,,answer is NSAID induced pre renal AKI[due to pathology at arteriolar level]